



m.yamini.md









Patient is a 67 y/o woman that was referred to this center to ERCP.

She has had an surgical cholecystectomy in last week and after surgery

Has had persistent abdominal pain in epigastrium and suspicious to biliary leakage.

In ph/E abdomen is tender in epigastrium but not guard.

PMH:

COPD

DLP

Hb	11.9
WBC	11400
plt	156000
Cr	0.6
AST	30
ALT	15
ALP	362
Tot bil	2.2
D bil	1.3

نموده اند که با استفاده از روش *case* برآید. که میفرمایند (درست است)  
باید *case* را از *case* جدا کرد و به صورت مجزا درآید.



با این روش می توان آنرا به صورت دیگر نیز نوشت.

هر دو روش با استفاده از پارامتر *case* در دسترس است و هر دو روش به یک روش  
مانند هستند.

این روش در *case* در دسترس است و هر دو روش به یک روش  
مانند هستند.

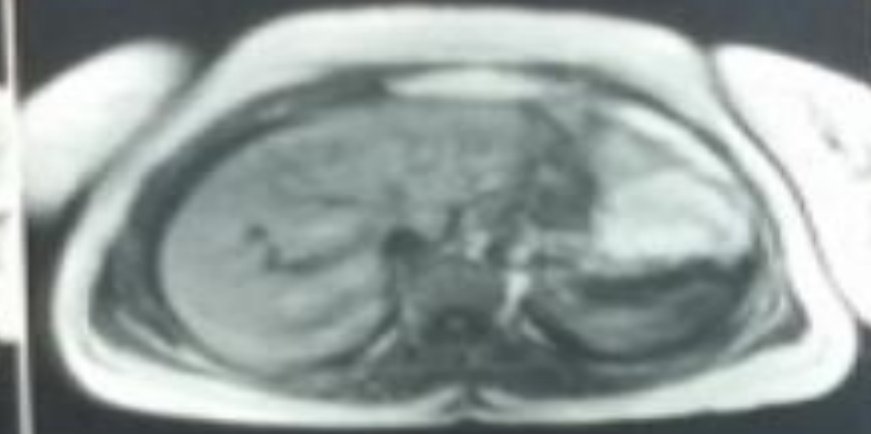
همه اینها در دسترس است و هر دو روش به یک روش  
مانند هستند.

در صورتی که *stable* به روش دیگر نیز می توان نوشت.  
این روش به یک روش  
مانند هستند.



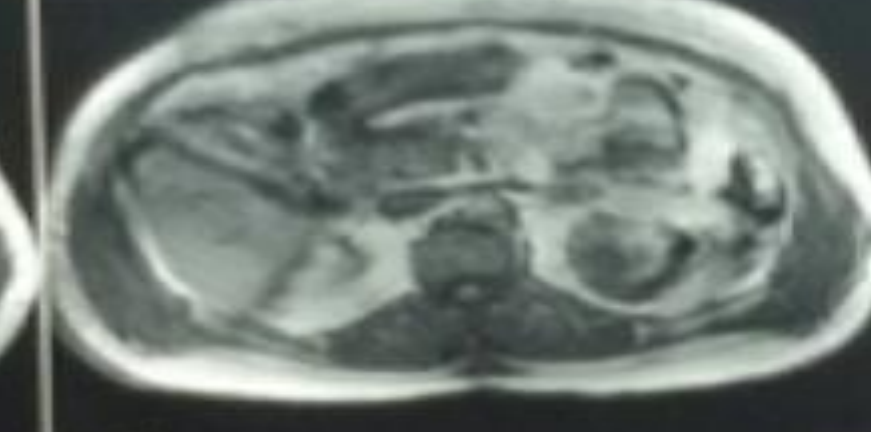


KONALTRONAM, BIRCH...  
12/1/2007  
9 05 12 00  
12/1/2007



TR 1200.0  
TE 5.7  
SL 6.5/5.2  
TA 11.00.2  
FOV 300.400

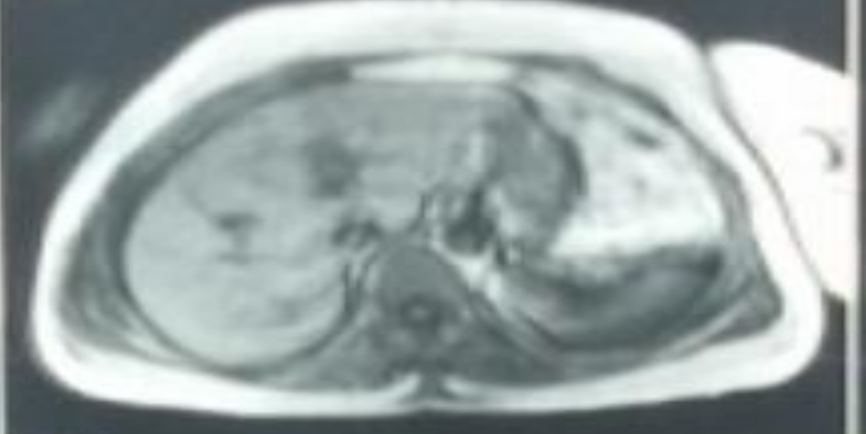
KONALTRONAM, BIRCH...  
12/1/2007  
9 05 12 00  
12/1/2007



TR 1200.0  
TE 5.7  
SL 6.5/5.2  
TA 11.00.2  
FOV 300.400

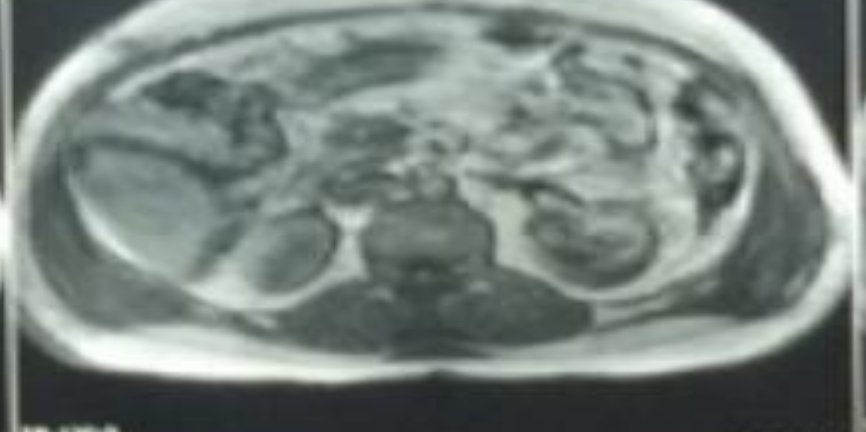
KONALTRONAM, BIRCH...  
12/1/2007  
9 05 12 00

KONALTRONAM, BIRCH...  
12/1/2007  
9 05 12 00  
12/1/2007



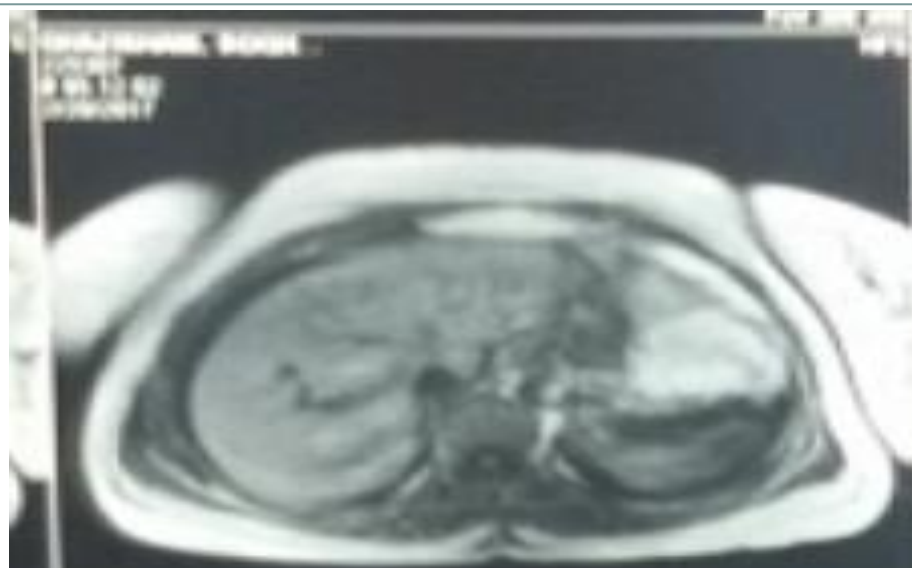
TR 1200.0  
TE 5.7  
SL 6.5/5.2  
TA 11.00.2  
FOV 300.400

KONALTRONAM, BIRCH...  
12/1/2007  
9 05 12 00  
12/1/2007

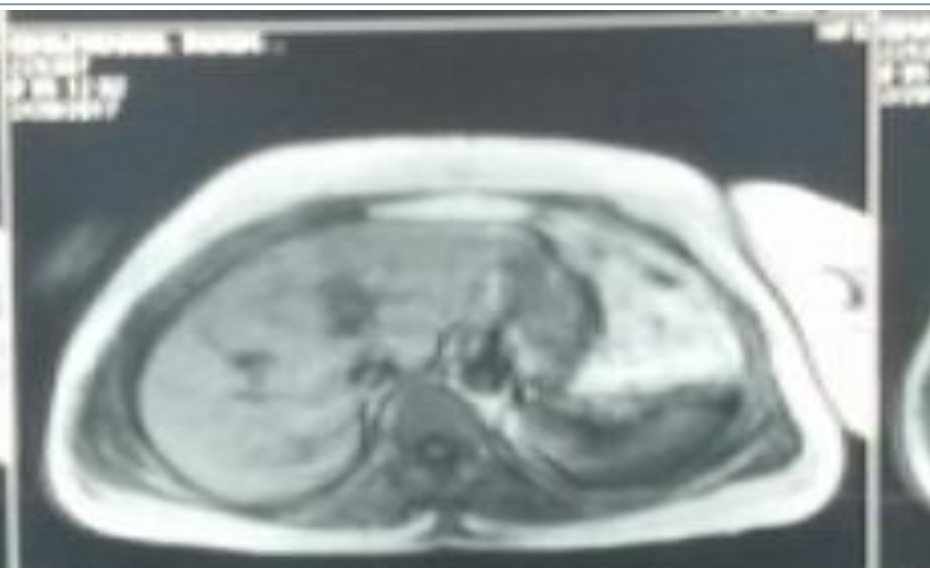


TR 1200.0  
TE 5.7  
SL 6.5/5.2  
TA 11.00.2  
FOV 300.400

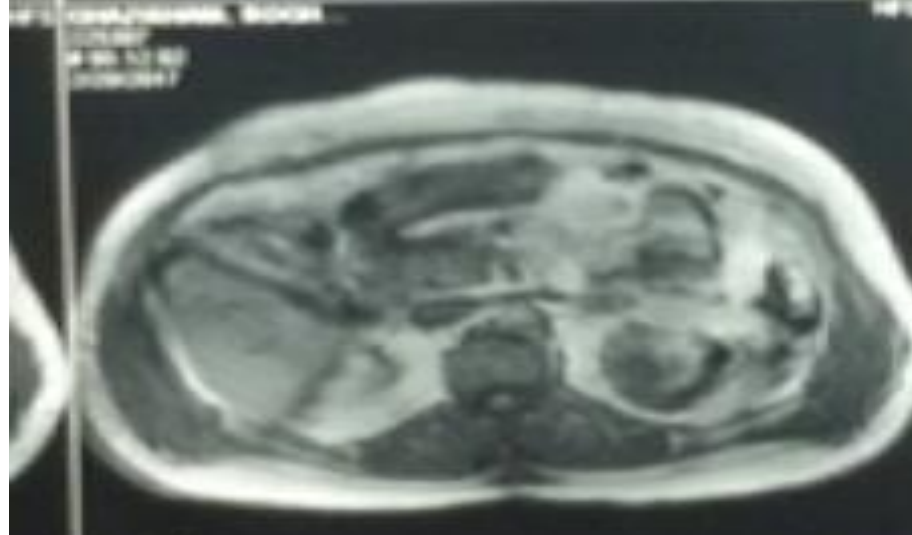KONALTRONAM, BIRCH...  
12/1/2007  
9 05 12 00



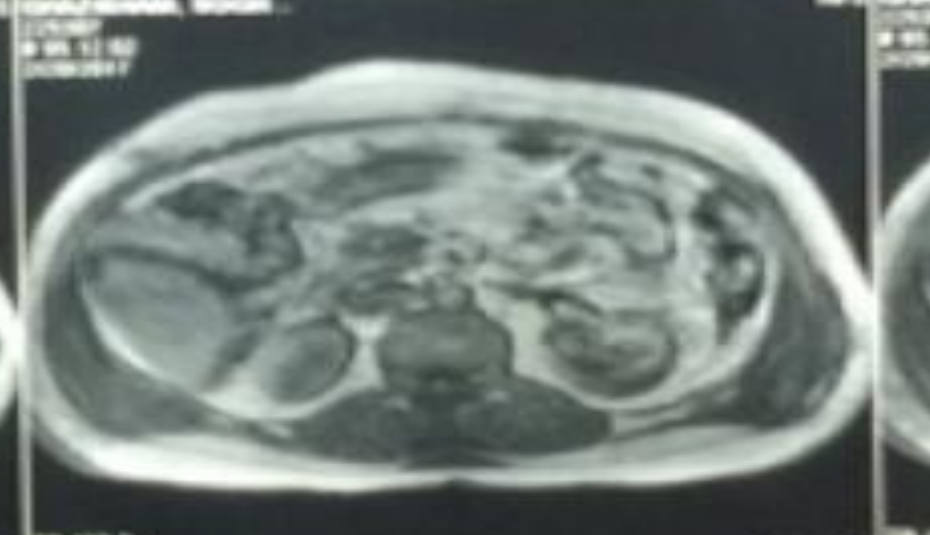TR 120.0  
TE 5.7  
SA 11.00.2  
SP 400.0  
SL 6.000.2  
Fov 300.000



TR 120.0  
TE 5.7  
SA 11.00.2  
SP 400.0  
SL 6.000.2  
Fov 300.000

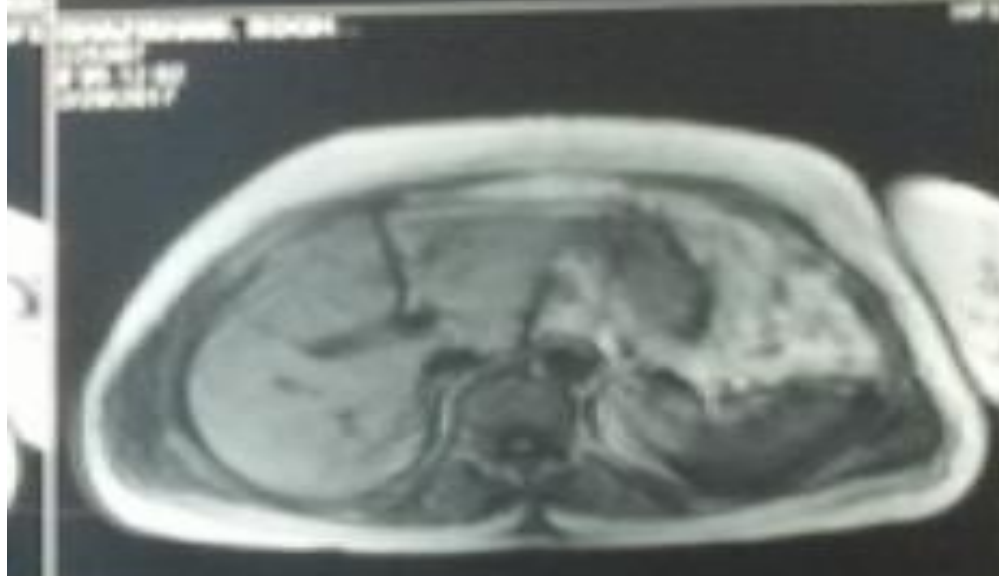

TR 120.0  
TE 5.7  
SA 11.00.2  
SP 400.0  
SL 6.000.2  
Fov 300.000

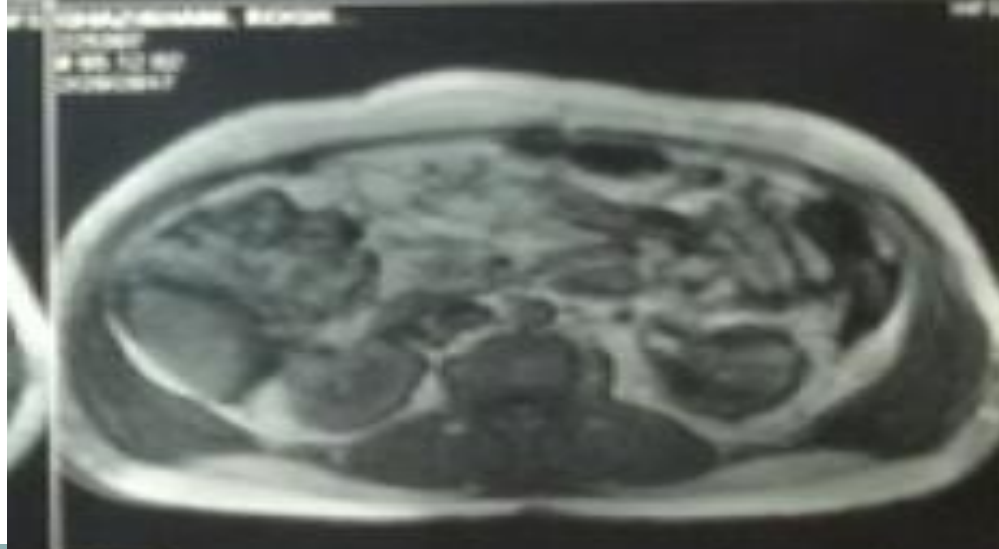

TR 120.0  
TE 5.7  
SA 11.00.2  
SP 400.0  
SL 6.000.2  
Fov 300.000

TR 130.0  
TE 3.7  
TA 11.48.2  
SP 47.1  
SL 8.515.2  
FLY 300.000  
MR 5

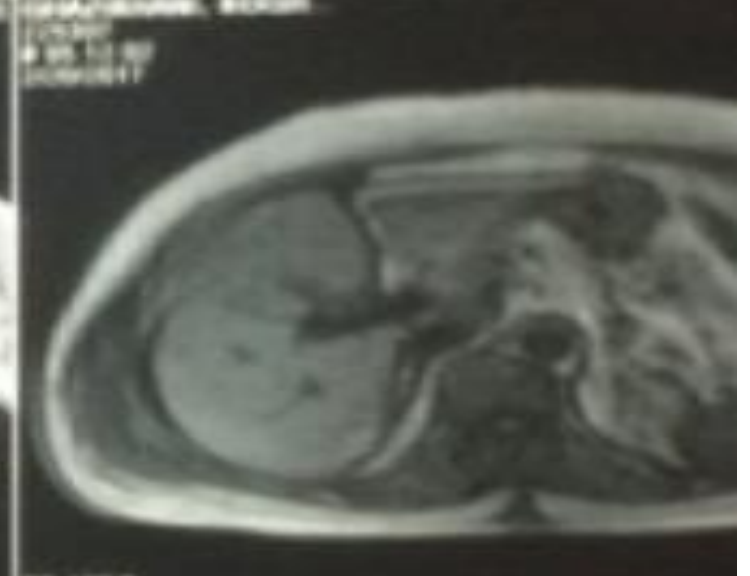

TR 130.0  
TE 3.7  
TA 11.48.2  
SP 47.1  
SL 8.515.2  
FLY 300.000  
MR 5

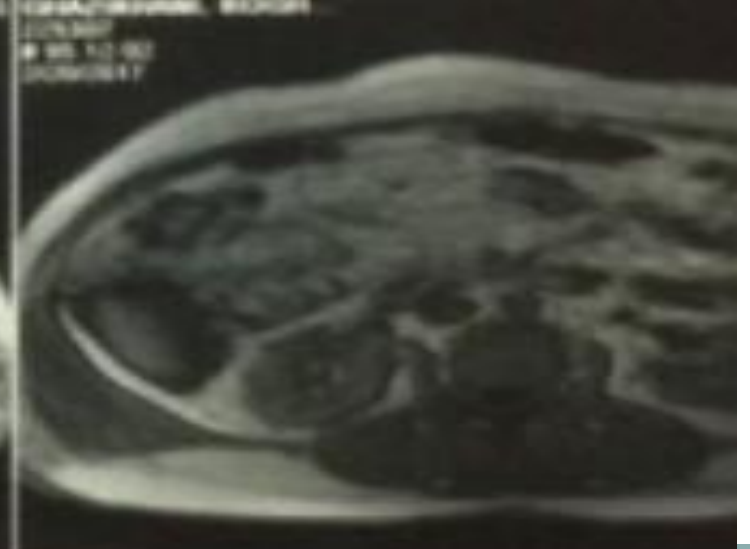

TR 130.0  
TE 3.7  
TA 11.48.2  
SP 47.1  
SL 8.515.2  
FLY 300.000  
MR 5

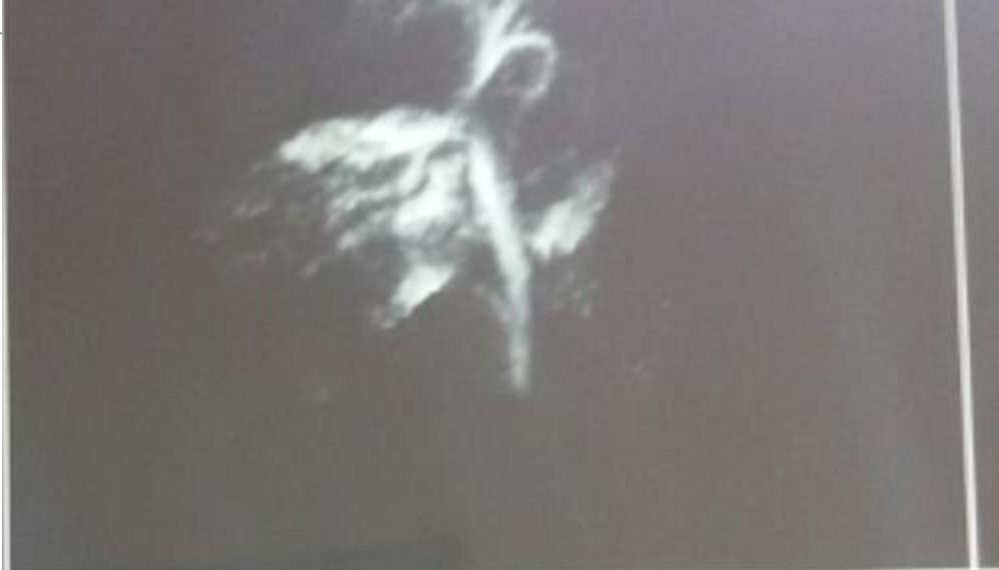
TR 130.0  
TE 3.7  
TA 11.48.2  
SP 47.1  
SL 8.515.2  
FLY 300.000  
MR 5



TR 130.0  
TE 3.7  
TA 11.48.2  
SP 47.1  
SL 8.515.2  
FLY 300.000  
MR 5

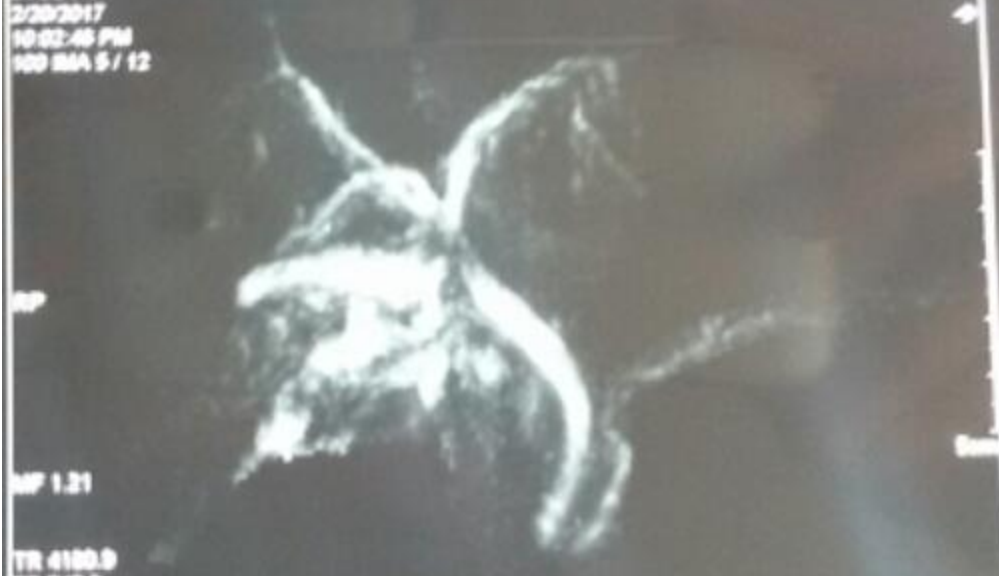

TR 130.0  
TE 3.7  
TA 11.48.2  
SP 47.1  
SL 8.515.2  
FLY 300.000  
MR 5



ONADRUHAM, SOONAVE  
229007  
3/20/1995, F, 62Y  
# 85.12.02  
STUDY 1  
3/20/2017  
10:02:40 PM  
100 MA 5 / 12

Head  
Axial  
MR 2017  
NPS  
+LPO



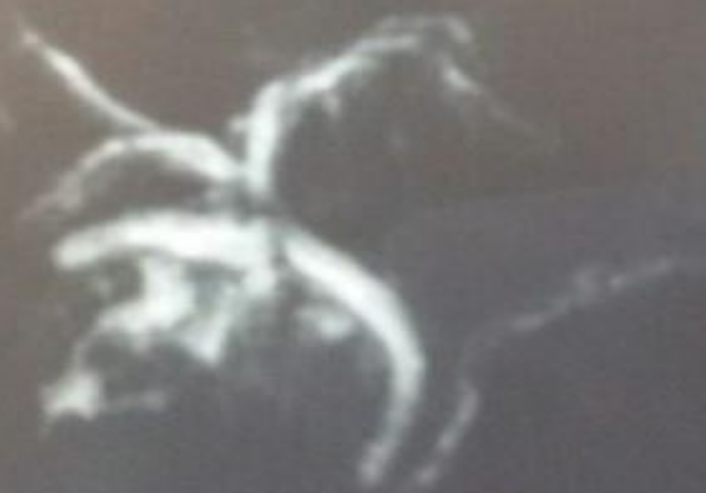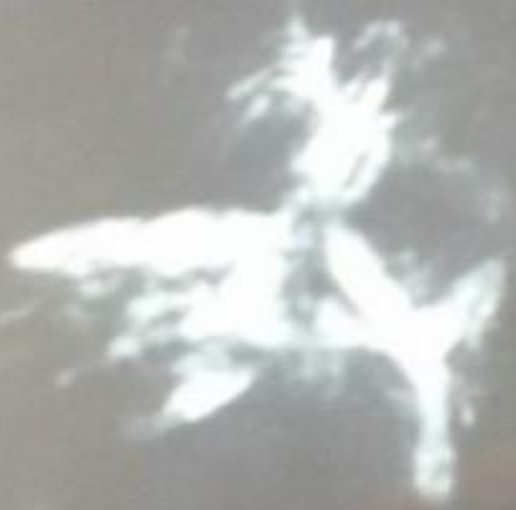AP

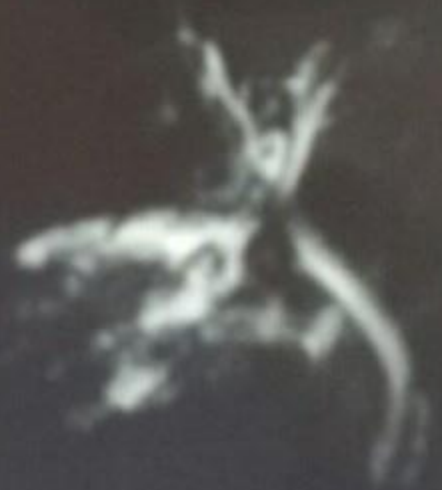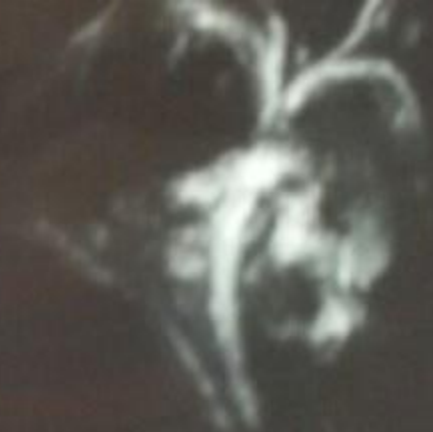MP 1.21

TR 4100.0  
TE 760.0  
SN 372.0  
MIP-COMMANIPULATED

A2000PS

Case: 2017-10-2  
U 2017





۹۸-۱۲-۷


وقت قاضی

nrep.


Gall bladder is not visualized.  
 Free fluid at right and left subdiaphragmatic spaces and right subhepatic space and spleno-renal space is seen.

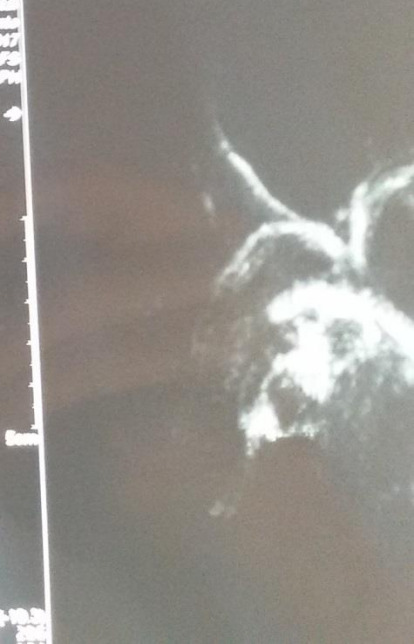
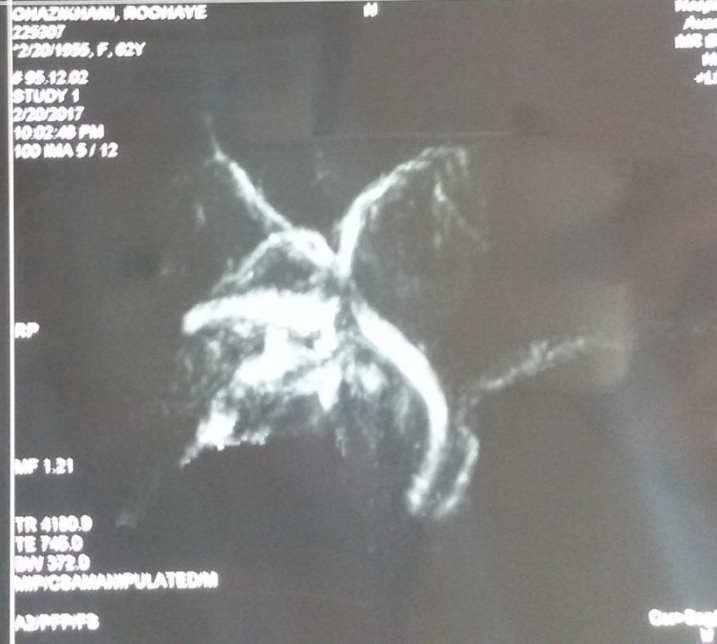
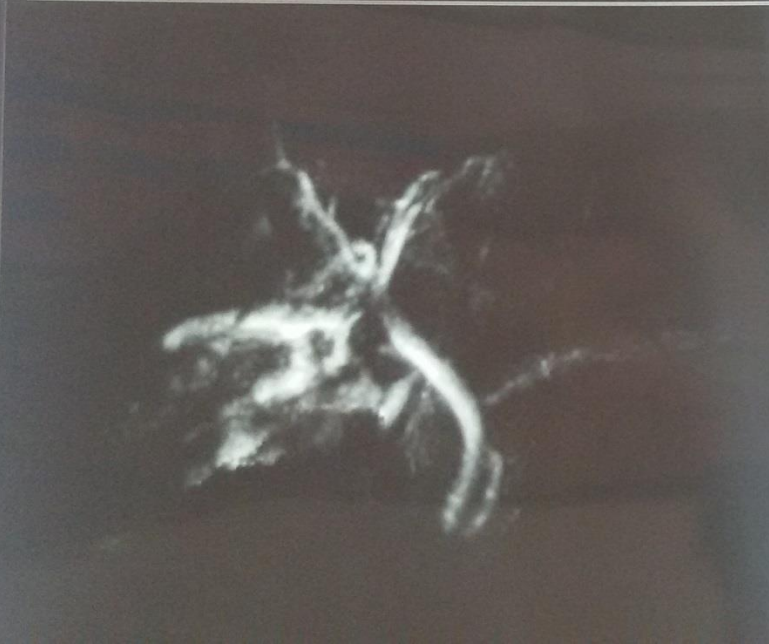
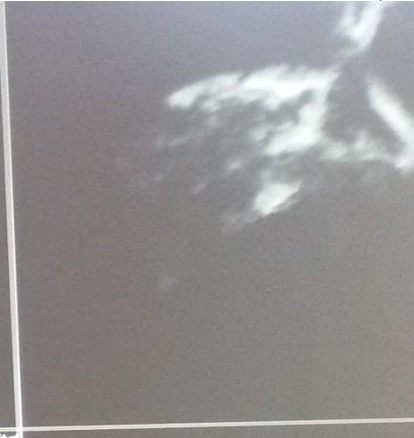
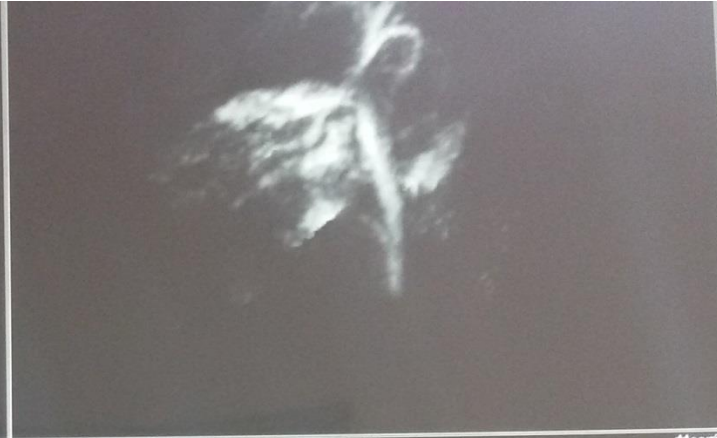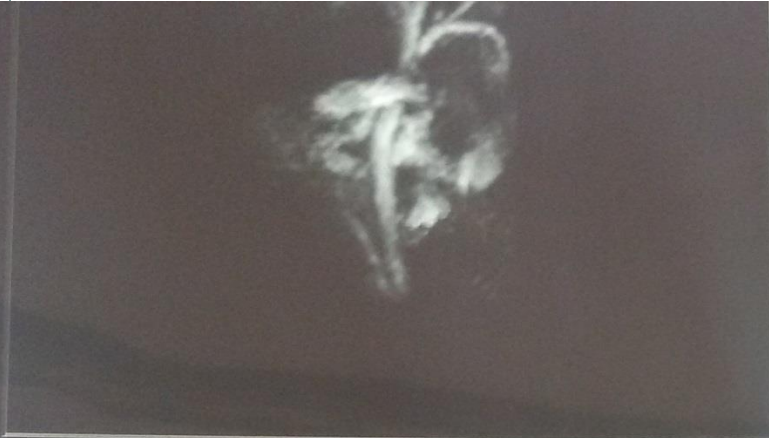billiary ducts are normal.  
 Pancreatic duct is normal.











OMAZKANI, ROOHAVE  
229207  
2/20/1986, F, 62Y  
# 95.12.02  
STUDY 1  
2/20/2017  
10:02:46 PM  
100 MRA 5 / 12

RP

MF 1.21

TR 4180.0  
TE 745.0  
BW 372.0  
MIP/CORONARIPULATEDM  
AS/PP/PS

Monitor  
Amplitude  
100 002  
MFS  
+1.5PM

Cur-Seq-10.2  
V  
2017

