

# EASL Clinical Practice Guidelines: Wilson's disease

European Association for the Study of the Liver\*

## Summary

This Clinical Practice Guideline (CPG) has been developed to assist physicians and other healthcare providers in the diagnosis and management of patients with Wilson's disease. The goal is to describe a number of generally accepted approaches for diagnosis, prevention, and treatment of Wilson's disease. Recommendations are based on a systematic literature review in the Medline (PubMed version), Embase (Dialog version), and the Cochrane Library databases using entries from 1966 to 2011. The Grades of Recommendation, Assessment, Development, and Evaluation (GRADE) system used in other EASL CPGs was used and set against the somewhat different grading system used in the AASLD guidelines (Table 1A and B). Unfortunately, there is not a single randomized controlled trial conducted in Wilson's disease which has an optimal design. Thus, it is impossible to assign a high or even a moderate quality of evidence to any of the questions dealt with in these guidelines. The evaluation is mostly based on large case series which have been reported within the last decades.

© 2011 European Association for the Study of the Liver. Published by Elsevier B.V. All rights reserved.

## Introduction

Normal dietary consumption and absorption of copper exceed the metabolic need, and homeostasis of this element is maintained exclusively by the biliary excretion of copper. Wilson's disease is an inherited disorder in which defective biliary excretion of copper leads to its accumulation, particularly in liver and brain [1,2]. Wilson's disease is due to mutations of the *ATP7B* gene on chromosome 13 [3,4], which encodes a copper-transporting P-type ATPase (*ATP7B*) residing in the trans-Golgi network of hepatocytes. *ATP7B* is responsible for transporting copper from intracellular chaperone proteins into the secretory pathway, both for excretion into bile and for incorporation into apo-ceruloplasmin for the synthesis of functional ceruloplasmin [3,4]. The development of Wilson's disease is due to the accumulation of copper in affected tissues.

Clinical presentation can vary widely, but the key features of Wilson's disease are liver disease and cirrhosis, neuropsychiatric disturbances, Kayser–Fleischer rings in Descemet's membrane of the cornea, and acute episodes of hemolysis often in association

with acute liver failure. Wilson's disease is not just a disease of children and young adults, but may present at any age [5].

Wilson's disease is a genetic disorder that is found worldwide. Wilson's disease is recognized to be more common than previously thought, with a gene frequency of 1 in 90–150 and an incidence (based on adults presenting with neurologic symptoms [6]) that may be as high as 1 in 30,000 [7]. More than 500 distinct mutations have been described in the Wilson gene, from which 380 have a confirmed role in the pathogenesis of the disease [8].

## Clinical presentation

The most common presentations are with liver disease or neuropsychiatric disturbances. Asymptomatic patients are most often detected by family screening.

### Age at onset of symptoms

Wilson's disease may present symptomatically at any age, although the majority presents between ages 5 and 35. The youngest patient reported with cirrhosis due to Wilson's disease was 3-years-old [9]. About 3% of patients present beyond the fourth decade, either with hepatic or neurologic disease [5]. The oldest patients diagnosed were in their eighth decade [10,11].

### Physical signs

The clinical hallmark of Wilson's disease is the Kayser–Fleischer ring, which is present in 95% of patients with neurologic symptoms and somewhat over half of those without neurologic symptoms [12,13]. In children presenting with liver disease, Kayser–Fleischer rings are usually absent [14]. Kayser–Fleischer rings are caused by deposition of copper in Descemet's membrane of the cornea. A slit-lamp examination by an experienced observer is required to identify Kayser–Fleischer rings. They are not entirely specific for Wilson's disease, since they may be found in patients with chronic cholestatic diseases including children with neonatal cholestasis. Other ophthalmologic changes are rare and include sunflower cataracts, which are caused by deposits of copper in the center of the lens. They can also be found by slit-lamp examination [15].

Neurologic signs are variable, most often tremor, ataxia, and dystonia. Signs of liver disease are nonspecific, but any liver

Received 28 November 2011; accepted 28 November 2011

\* Correspondence: EASL Office, 7 rue des Batoirs, CH 1205 Geneva, Switzerland. Tel.: +41 22 807 0360; fax: +41 22 328 0724.

E-mail address: easloffice@easloffice.eu

Contributors: Chairman: Peter Ferenci. Clinical Practice Guidelines Members: Anna Czlonkowska, Wolfgang Stremmel, Roderick Houwen, William Rosenberg, Michael Schilsky. EASL Governing Board Representatives: Peter Jansen and Darius Moradpour. Reviewer(s): Jonathan Gitlin.



ELSEVIER

## Clinical Practice Guidelines

**Table 1. (A) GRADE system as used in EASL Clinical Practice Guidelines [159]. (B) System of Recommendations as used in AASLD Practice Guidelines [130].**

A		
Grade	Evidence	
I	Randomized controlled trials	
II-1	Controlled trials without randomization	
II-2	Cohort or case-control analytic studies	
II-3	Multiple time series, dramatic uncontrolled experiments	
III	Opinions of respected authorities, descriptive epidemiology	
Evidence		
Evidence	Description	
High quality	Further research is very unlikely to change our confidence in the estimated effect	A
Moderate quality	Further research is likely to have an important impact on our confidence in the estimate effect and may change the estimate	B
Low quality	Further research is likely to have an important impact on our confidence in the estimate effect and is likely to change the estimate. Any change of estimate is uncertain	C
Recommendation		
Recommendation	Description	
Strong	Factors influencing the strength of recommendation included the quality of evidence, presumed patient-important outcomes and costs	1
Weak	Variability in preferences and values, or more uncertainty. Recommendation is made with less certainty, higher costs or resource consumption	2
B		
Classification	Description	
Class I	Conditions for which there is evidence and/or general agreement that a given procedure or treatment is beneficial, useful, and effective	
Class II	Conditions for which there is conflicting evidence and/or a divergence of opinion about the usefulness/efficacy of a procedure or treatment	
Class IIa	Weight of evidence/opinion is in favor of usefulness/efficacy	
Class IIb	Usefulness/efficacy is less well established by evidence/opinion	
Class III	Conditions for which there is evidence and/or general agreement that a procedure/treatment is not useful/effective and in some cases may be harmful.	
Level of evidence		
Level of evidence	Description	
Level A	Data derived from multiple randomized clinical trials or meta-analyses	
Level B	Data derived from a single randomized trial, or nonrandomized studies	
Level C	Only consensus opinion of experts, case studies, or standard of care	

disease of unknown origin should be considered as Wilson's disease until proved otherwise. Diagnostic vigilance is important because Kayser–Fleischer rings may be absent in up to 50% of patients with Wilson's disease affecting the liver [12].

### Liver disease

Any type of liver disease may be encountered in patients with Wilson's disease. Clinically evident liver disease may precede neurologic manifestations by as much as 10 years and most patients with neurologic symptoms have some degree of liver disease at presentation. Presenting symptoms of liver disease can be highly variable, ranging from asymptomatic, with only biochemical abnormalities, to overt cirrhosis with all its complications. Wilson's disease may also present as acute hepatic failure sometimes associated with Coombs-negative hemolytic anemia and acute renal failure. Patients diagnosed with Wilson's disease who have a history of jaundice may have previously experienced an episode of hemolysis. Clinical symptoms are summarized in Table 2.

### Acute liver failure due to Wilson's disease (former: "fulminant Wilson's disease")

Wilson's disease enters into the differential diagnosis of any young patient presenting with acute hepatitis. Its clinical presentation may be indistinguishable from that of acute viral hepatitis, with jaundice and abdominal discomfort. In some patients symptoms resolve spontaneously, but once the diagnosis is made, lifelong treatment is necessary. On the other hand, rapid deterioration can occur with acute liver failure.

Wilson's disease accounts for 6–12% of all patients with acute liver failure who are referred for emergency transplantation [16,17]. Although cirrhosis is already present in most cases, the clinical presentation is acute and progresses rapidly to hepatic and renal failure and, when untreated, carries an almost 95% mortality. Acute liver failure due to Wilson's disease occurs predominantly in young females (female:male ratio 4:1) [18]. An acute presentation with rapid deterioration may also occur in patients who were previously treated but stopped their medications [16]. Suspicion for acute Wilson's disease should be particularly high in patients with deep jaundice, low haemoglobin, low cholinesterase [17], only mildly increased transaminases, and low alkaline phosphatase.

### Chronic hepatitis and cirrhosis

Many patients present with signs of chronic liver disease and evidence of cirrhosis, either compensated or decompensated. Patients may present with isolated splenomegaly due to clinically inapparent cirrhosis with portal hypertension. The presentation may be indistinguishable from other forms of chronic active hepatitis, with symptoms including jaundice, malaise, and vague abdominal complaints.

### Hemolysis

Coombs-negative haemolytic anemia may be the only initial symptom of Wilson's disease. However, marked hemolysis is commonly associated with severe liver disease. Decay of liver cells may result in the release of large amounts of stored copper, which further aggravates hemolysis. In one series, hemolysis was a presenting feature in 25 out of 220 cases (12%); in these patients hemolysis occurred either as a single acute episode or

**Table 2. Clinical symptoms in Wilson's disease patients presenting with liver disease.**

Author, Country, [Ref.]	Walshe, UK, [157]	Stremmel <i>et al.</i> , Germany, [39]	Schilsky <i>et al.</i> , USA, [142]	Scott <i>et al.</i> , UK, [158]	Ferenci, Austria, [44]
N with liver disease (out of)	87 (>250)	n.a. (51)	20* (320)	17* (45)	30 (64)
Presenting symptom					
Jaundice, anorexia, vomiting (%)	44	14	15	41	37
Ascites/edema (%)	26	14	50	24	23
Variceal hemorrhage (%)	6		10	6	3
Hemorrhagic diathesis (%)	8				3
Hemolysis (%)	20	10	5		10
Hepatomegaly/splenomegaly (%)	16	49	15	29	17
Acute liver failure (%)	n.a.	n.a.	n.a.	n.a.	17
Asymptomatic <sup>§</sup> (%)		18	5		23

\*Only cases with chronic active hepatitis.

§Elevated ALT at routine testing, or accidental finding of cirrhosis or of Kayser–Fleischer rings.

recurrently or was low-grade and chronic [18]. In a series of 283 Japanese patients with Wilson's disease, only three presented with acute hemolysis alone [19]. One quarter of the patients presenting with jaundice also had hemolysis. Acute liver disease and hemolysis as a presenting symptom can occur during delivery, mimicking HELLP syndrome [20]. Low-grade hemolysis may be associated with Wilson's disease even when liver disease is not clinically evident. Some patients presenting with neurologic symptoms report that they have experienced transient episodes of jaundice previously, probably due to hemolysis [21]. On the other hand, rapid deterioration can occur with acute liver failure.

### Neurologic disease

Wilson's disease can manifest with an impressive spectrum of neurological, behavioral or psychiatric disorders, which may be its first clinical manifestation, appearing simultaneously with hepatic signs, or some years later.

Neurological presentation can be extremely subtle, and intermitted for many years, but may also develop very rapidly, leading within a few months to complete disability. The neurological abnormalities can be classified as: (1) Akinetic-rigid syndrome similar to Parkinson's disease; (2) Pseudosclerosis dominated by tremor; (3) Ataxia; and (4) Dystonic syndrome. In many cases, neurological signs are very difficult to classify as patients can have more than one abnormality, each with different levels of severity.

The characteristic tremor is a coarse, irregular proximal tremulousness with a "wing beating" appearance. Dystonia can be focal, segmental or very severe, involving all parts of the body, leading to severe contractures. Very common motor impairments involve the cranial region, and manifest clinically as dysarthria (can be cerebellar or extrapyramidal leading to aponia), drooling or oropharyngeal dystonia. Facial grimacing, open jaw, running saliva, and lip retraction are characteristic manifestations. Speech changes and drooling are often early neurologic symptoms. A tremor-rigidity syndrome ("juvenile Parkinsonism") should raise suspicion of Wilson's disease [22–24].

Because of an increasing difficulty in controlling movement or progressive dystonia, patients become bedridden and unable to care for themselves. Ultimately, the patient becomes severely disabled, usually alert, but unable to talk. In patients presenting

with advanced liver disease, neurologic symptoms can be mistaken for signs of hepatic encephalopathy.

### Psychiatric symptoms

Behavioral and psychiatric symptoms are common and some of them may precede neurologic or hepatic signs and symptoms. About one-third of patients initially present with psychiatric abnormalities. In children with Wilson's disease, declining school performance, personality changes, impulsiveness, labile mood, sexual exhibitionism, and inappropriate behavior are observed [24,25]. The initial symptoms are frequently misdiagnosed as behavioral problems associated with puberty. In older persons, psychotic features resembling paranoia, schizophrenia or depression can be observed but behavioral changes are also common. Severe cognitive deterioration is observed in patients with advanced neurological disease, but in general, cognitive function is not markedly impaired [26].

A delay in diagnosing Wilson's disease in patients with neuropsychiatric presentations is frequent and was in one case as long as 12 years [27]. Patients presenting with neuropsychiatric symptoms may have concurrent symptomatic liver disease, but in most patients liver disease can only be detected by laboratory evaluation, imaging studies of the liver or by liver histology. About half of the patients have advanced fibrosis or frank cirrhosis. On the other hand, signs of liver disease may be even completely absent at biopsy [28].

### Other clinical manifestations

Less common presentations include gigantism, lunulae, renal abnormalities including aminoaciduria and nephrolithiasis, hypercalciuria and nephrocalcinosis [29,30], cardiomyopathy [31], myopathy [32], chondrocalcinosis and osteoarthritis [33], hypoparathyroidism [34], pancreatitis [35], infertility or repeated miscarriages [36,37].

### Prognosis

Untreated Wilson's disease is universally fatal, with most patients dying from liver disease and a minority from complications of

## Clinical Practice Guidelines

**Table 3. Prognostic index in Wilson's disease [40], modified by Dhawan *et al.* [41].**

	1*	2*	3*	4*
Serum bilirubin ( $\mu\text{mol/L}$ )	100-150	151-200	201-300	>300
AST (U/L)	100-150	151-300	301-400	>400
INR	1.3-1.6	1.7-1.9	2.0-2.4	>2.4
WBC [ $10^9/\text{L}$ ]	6.8-8.3	8.4-10.3	10.4-15.3	>15.3
Albumin [g/L]	34-44	25-33	21-24	<21

\*= score points, upper limit of normal for AST = 20 IU/ml (at King's College). A score  $\geq 11$  is associated with high probability of death without liver transplantation.

progressive neurologic disease. With chelation treatment and liver transplantation, prolonged survival has become the norm [27,38,39], although mortality has not been assessed prospectively. In general, prognosis for survival depends on the severity of liver and neurological disease and compliance with drug treatment. Liver function becomes normal over 1–2 years of treatment in most patients with no or compensated cirrhosis at presentation, and then remains stable without progressive liver disease with adherence to treatment. At the other end of the spectrum, medical therapy is rarely effective in patients presenting with acute liver failure due to Wilson's disease, mainly due to the time required to remove toxic copper from the organism. A prognostic index has been developed [40], and later modified by Dhawan *et al.* [41]. A score greater than 11 is always fatal without liver transplantation (Table 3). Patients presenting with neurologic symptoms fare better with respect to life expectancy, especially if liver disease is limited. However, neurologic symptoms appear to be only partly reversible with treatment and may even worsen following initiation of treatment.

In patients undergoing orthotopic liver transplantation, survival may be slightly reduced early on, but appears normal (for transplant population) thereafter [42].

### Differential diagnosis

Acute hepatitis with Wilson's disease presents similarly to any other acute cases of hepatitis. Similarly, Wilson's disease should

enter into the diagnosis of all patients with chronic hepatitis and cirrhosis, as routine histologic changes are nonspecific. Wilson's disease should be considered when acute hepatitis is accompanied by rapid onset of jaundice and hemolytic anemia. During adolescence, Wilson's disease presenting with neurologic symptoms may be misdiagnosed as a behavioural problem because initial symptoms may be subtle. More advanced movement disorders in a young person should provoke consideration of Wilson's disease, but the diagnosis may be overlooked where the presentation suggests a primarily psychological or psychiatric disorder.

### Diagnostic methods

Typically, the combination of Kayser–Fleischer rings and a low serum ceruloplasmin (<0.1 g/L) level is sufficient to establish a diagnosis. When Kayser–Fleischer rings are not present (as is common in the hepatic manifestation of Wilson's disease), ceruloplasmin levels are not always reliable because they may be low for reasons other than Wilson's disease (e.g. autoimmune hepatitis, severe hepatic insufficiency in advanced liver disease, celiac disease, familial aceruloplasminemia) [43] or in heterozygous carriers of *ATP7B* mutations who do not show copper overload disease. On the other hand, inflammation in the liver or elsewhere may cause the ceruloplasmin concentration to rise to normal levels, reflecting its identity as an acute phase protein. This is also true for treatment with estrogens. Thus, for many patients, a combination of tests reflecting disturbed copper metabolism may be needed. Not a single test is *per se* specific and, thus, a range of tests has to be applied (Table 4). A diagnostic score based on all available tests was proposed by the Working Party at the 8th International Meeting on Wilson's disease, Leipzig 2001 [44] (Table 5). The Wilson's disease scoring system provides a good diagnostic accuracy [45]. The diagnostic algorithm based on this score is shown in Fig. 1.

### Serum ceruloplasmin

Ceruloplasmin is the major carrier of copper in the blood. It contains six copper atoms per molecule (holoceruloplasmin) but may be present just as the protein without the copper

**Table 4. Routine tests for diagnosis of Wilson's disease.**

Test	Typical finding	False "negative"	False "positive"
Serum ceruloplasmin	Decreased by 50% of lower normal value	Normal levels in patients with marked hepatic inflammation Overestimation by immunologic assay Pregnancy, estrogen therapy	Low levels in: - malabsorption - aceruloplasminemia - heterozygotes
24-hour urinary copper	>1.6 $\mu\text{mol}/24\text{ h}$ >0.64 $\mu\text{mol}/24\text{ h}$ in children	Normal: - incorrect collection - children without liver disease	Increased: - hepatocellular necrosis - cholestasis - contamination
Serum "free" copper	>1.6 $\mu\text{mol/L}$	Normal if ceruloplasmin overestimated by immunologic assay	
Hepatic copper	>4 $\mu\text{mol/g}$ dry weight	Due to regional variation - in patients with active liver disease - in patients with regenerative nodules	Cholestatic syndromes
Kayser-Fleischer rings by slit lamp examination	Present	Absent - in up to 50% of patients with hepatic Wilson's disease - in most asymptomatic siblings	Primary biliary cirrhosis

Table 5. Scoring system developed at the 8th International Meeting on Wilson's disease, Leipzig 2001 [44].

Typical clinical symptoms and signs		Other tests	
KF rings		Liver copper (in the absence of cholestasis)	
Present	2	>5x ULN (>4 µmol/g)	2
Absent	0	0.8-4 µmol/g	1
Neurologic symptoms**		Normal (<0.8 µmol/g)	-1
Severe	2	Rhodanine-positive granules*	1
Mild	1	Urinary copper (in the absence of acute hepatitis)	
Absent	0	Normal	0
Serum ceruloplasmin		1-2x ULN	1
Normal (>0.2 g/L)	0	>2x ULN	2
0.1-0.2 g/L	1	Normal, but >5x ULN after D-penicillamine	2
<0.1 g/L	2	Mutation analysis	
Coombs-negative hemolytic anemia		On both chromosomes detected	4
Present	1	On 1 chromosome detected	1
Absent	0	No mutations detected	0
TOTAL SCORE		Evaluation:	
4 or more		Diagnosis established	
3		Diagnosis possible, more tests needed	
2 or less		Diagnosis very unlikely	

\*If no quantitative liver copper available, \*\*or typical abnormalities at brain magnetic resonance imaging. KF, Kayser-Fleischer; ULN, upper limit of normal.

(apoceruloplasmin). Ceruloplasmin is an acute phase reactant possessing a ferroxidase activity [46]. Levels of serum ceruloplasmin may be measured enzymatically by its copper-dependent oxidase activity towards specific substrates, or by antibody-dependent assays such as radioimmunoassay, radial immunodiffusion, or nephelometry. Immunologic assays may overestimate ceruloplasmin concentrations since they do not discriminate between apoceruloplasmin and holoceruloplasmin. The normal concentration of ceruloplasmin measured by the enzymatic assay varies among laboratories (with a lower limit between 0.15 and 0.2 g/L). In Wilson's disease, it is usually lower than 0.1 g/L. Serum ceruloplasmin concentrations are elevated by acute inflammation, in states associated with hyperestrogenemia such as pregnancy and estrogen supplementation. Serum ceruloplas-

min is typically decreased in patients with neurologic Wilson's disease, but may be in the low normal range in about half of patients with active Wilson's liver disease. On the other hand, serum ceruloplasmin may be low in other conditions with marked renal or enteric protein loss, malabsorption syndromes or with severe end-stage liver disease of any etiology. Approximately 20% of heterozygotes have decreased levels of serum ceruloplasmin [1,47]. Patients with aceruloplasminemia lack the protein entirely due to mutations in the ceruloplasmin gene on chromosome 3. These patients may exhibit hemosiderosis but do not have copper accumulation [48]. Thus, serum ceruloplasmin alone is not sufficient to diagnose or to exclude Wilson's disease. A prospective study on serum ceruloplasmin, as a screening test for Wilson's disease in patients referred with liver disease, showed that subnormal ceruloplasmin had a positive predictive value of only 6%. In children with Wilson's disease, 15-36% had ceruloplasmin in the normal range [14,49]. In one series, 12 out of 55 Wilson's disease patients had normal ceruloplasmin and no Kayser-Fleischer rings [12]. The predictive value of ceruloplasmin for diagnosis of Wilson's disease in acute liver failure is poor [50]. In one recently published study, measurement of serum ceruloplasmin oxidase activity was superior to immunologic assays for diagnosing Wilson's disease, but these assays are generally not available in routine labs [51].

Serum copper

Although a disease of copper overload, the total serum copper (which includes copper incorporated in ceruloplasmin) in Wilson's disease is usually decreased in proportion to the decreased ceruloplasmin in the circulation. In patients with severe liver injury, serum copper may be within the normal range, independent of whether serum ceruloplasmin levels are elevated or low. In the setting of acute liver failure due to Wilson's disease, levels of serum copper may even be markedly

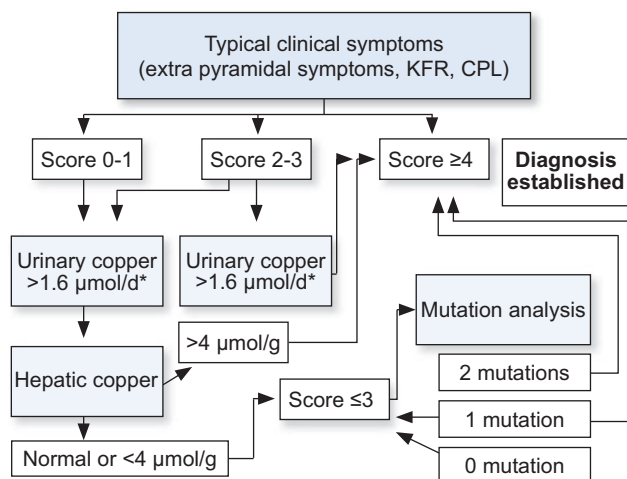


Fig. 1. Diagnostic algorithms for Wilson's disease based on the Leipzig Score [44]. \*In children the cut off can be lowered to 0.64 µmol/d.

## Clinical Practice Guidelines

elevated due to the sudden release of the metal from liver tissue stores. Normal or elevated serum copper levels, in the face of decreased levels of ceruloplasmin, indicate an increase in the concentration of copper which is not bound to ceruloplasmin in the blood (non-ceruloplasmin-bound copper). Non-ceruloplasmin-bound copper (or “free copper”) can be calculated by subtracting ceruloplasmin-bound copper ( $3.15 \times$  ceruloplasmin in mg/L equals the amount of ceruloplasmin-bound copper in  $\mu\text{g/L}$ ) from the total serum copper concentration (in  $\mu\text{g/L}$ ; serum copper in  $\mu\text{mol/L} \times 63.5$  equals serum copper in  $\mu\text{g/L}$ ) [52]. The serum non-ceruloplasmin-bound copper concentration has been proposed as a diagnostic test for Wilson’s disease [53]. In most untreated patients, it is elevated above  $200 \mu\text{g/L}$ . The serum non-ceruloplasmin copper concentration may be elevated in acute liver failure of any etiology, in chronic cholestasis [54], and in cases of copper intoxication. The major problem with non-ceruloplasmin-bound copper as a diagnostic test for Wilson’s disease is that it is dependent on the adequacy of the methods for measuring both serum copper and ceruloplasmin. It is of more value in monitoring pharmacotherapy than in the diagnosis of Wilson’s disease.

### Urinary copper excretion

The amount of copper excreted in the urine in a 24-hour period may be helpful for diagnosing Wilson’s disease and for monitoring treatment. In untreated patients, the 24-hour urinary excretion of copper reflects the amount of non-ceruloplasmin-bound copper in the circulation. The exact urine volume and the total creatinine excretion per 24 h are important for accurate determination of urinary copper excretion. In case of renal failure, the test is not applicable. In untreated symptomatic patients, “baseline” copper excretion greater than  $1.6 \mu\text{mol}/24 \text{ h}$  ( $100 \mu\text{g}/24 \text{ h}$ ) is taken as diagnostic of Wilson’s disease [5]. However, basal 24-hour urinary copper excretion may be less than  $1.6 \mu\text{mol}/24 \text{ h}$  at presentation in 16–23% of patients, especially in children and asymptomatic siblings [12,14,55]. Since urinary copper excretion is negligible in healthy individuals [56], a urinary copper excretion above  $0.64 \mu\text{mol}/24 \text{ h}$  can be suggestive of Wilson’s disease in asymptomatic children. The problems of measuring 24-hour copper excretion include incomplete urine collection, and, on the other hand, copper contamination of the collection device (this being less problematic with the advent of disposable containers). Interpreting 24-hour urinary copper excretion can be difficult due to the overlap with findings in other types of liver disease (e.g. autoimmune hepatitis, chronic active liver disease or cholestasis and in particular during acute hepatic failure of any origin). Heterozygotes may also have higher copper excretion than controls, rarely exceeding the normal range levels [57].

Urinary copper excretion with D-penicillamine administration was thought to be a useful diagnostic test. This test has only been standardized in a pediatric population in which 500 mg of D-penicillamine was administered orally at the beginning and again 12 h later during the 24-hour urine collection, irrespective of body weight [58]. Compared with a spectrum of other liver diseases, including autoimmune hepatitis, primary sclerosing cholangitis, and acute liver failure, a clear differentiation was found when more than  $25 \mu\text{mol}/24 \text{ h}$  was excreted. A reassessment of this test in paediatric patients reconfirmed the value in the diagnosis of Wilson’s disease with active liver disease, but was unreliable to exclude the diagnosis in asymptomatic siblings [59]. In

comparison to children with other liver diseases, the D-penicillamine test had only a sensitivity of 12.5%. However, data by Dhanwan *et al.* and by Nicastro *et al.* now suggest that using a lower threshold for urinary copper excretion (without D-penicillamine stimulation) of only  $0.64 \mu\text{mol}/24 \text{ h}$  increases sensitivity of the test and eliminates the need for the stimulation testing with D-penicillamine [41,45].

The penicillamine challenge test has been used in adults, but many of the reported results of this test utilized different dosages and timing for administration of the D-penicillamine [12,53,56]. Thus, this test is not recommended for diagnosis of Wilson’s disease in adults.

### Hepatic parenchymal copper concentration

Hepatic copper accumulation is the hallmark of Wilson’s disease. However, specific stains like rhodamine or orcein reveal focal copper stores in less than 10% of patients because they detect only lysosomal copper depositions. Thus, hepatic copper overload cannot be excluded by histochemical evaluation of a liver biopsy alone. Therefore, the measurement of hepatic parenchymal copper concentration is the method of choice for the diagnosis of Wilson’s disease. Biopsies for quantitative copper determination should be placed dry in a copper-free container. Shipment for quantitative copper determination does not require special precautions like freezing. In general, the accuracy of measurement is improved with adequate specimen size: at least 1 cm of biopsy core length should be submitted for analysis [62]. Paraffin-embedded specimens may also be analyzed for copper content, but may be less reliable if the specimen is small. Hepatic copper content  $>4 \mu\text{mol/g}$  dry weight is considered as the best biochemical evidence for Wilson’s disease. Lowering the threshold from  $4 \mu\text{mol/g}$  dry weight to  $1.2 \mu\text{mol/g}$  dry weight improved sensitivity from 83.3% to 96.5%, while specificity remained acceptable (95.4% vs. 98.6%) [28]. The major problem with hepatic parenchymal copper concentration is the inhomogeneous distribution of copper within the liver in later stages of Wilson’s disease. Thus, the concentration can be underestimated due to sampling error. In about 18% of adult patients, hepatic copper concentrations are only between 0.8 and  $4 \mu\text{mol/g}$  dry weight with a few even in the normal range [28]. In a pediatric study, sampling error was sufficiently common to render this test unreliable in patients with cirrhosis [60]. On the other hand, in long-standing cholestatic disorders, hepatic copper content may also be increased. Markedly elevated levels of hepatic copper may also be found in idiopathic copper toxicosis syndromes such as Indian childhood cirrhosis [61].

### Liver histology

For diagnostic purposes, a liver biopsy is only required if the clinical signs and noninvasive tests do not allow a final diagnosis or if there is suspicion of other or additional liver pathologies [62].

The earliest histologic abnormalities in the liver include mild steatosis (both microvesicular and macrovesicular), glycogenated nuclei in hepatocytes, and focal hepatocellular necrosis [62,63]. Frequently, these changes are misdiagnosed as nonalcoholic fatty liver disease (NAFLD) or nonalcoholic steatohepatitis (NASH). The liver biopsy may show classic histologic features of autoimmune hepatitis (the so-called “chronic active hepatitis” picture). With progressive parenchymal damage, fibrosis and subsequently cirrhosis develop. About half of the patients have cirrhosis at the

time of diagnosis [28]. There are a few older patients with Wilson's disease who do not have cirrhosis or even signs of liver disease [5,12]. In the setting of acute liver failure due to Wilson's disease, there is a marked hepatocellular degeneration and parenchymal collapse, typically on the background of cirrhosis. Apoptosis of hepatocytes is a prominent feature during the acute injury [64].

Detection of copper in hepatocytes by routine histochemical evaluation is highly variable. Especially in early stages of the disease, copper is mainly present in the cytoplasm bound to metallothionein and is not histochemically detectable [65]. The amount of copper varies from nodule to nodule in the cirrhotic liver and may vary from cell to cell in pre-cirrhotic stages. The absence of histochemically identifiable copper does not exclude Wilson's disease. Lysosomal copper complexes can be stained by various methods, including the rhodanine or orcein stain.

Ultrastructural analysis of liver specimens at the time steatosis is present reveals specific mitochondrial abnormalities [66]. Typical findings include variability in size and shape, increased density of the matrix material, and numerous inclusions including lipid and fine granular material that may be copper. The most striking alteration is increased intracristal space with dilatation of the tips of the cristae, creating a cystic appearance [66]. In the absence of cholestasis, these changes are considered to be essentially pathognomonic of Wilson's disease. At later stages of the disease, dense deposits within lysosomes are present. Ultrastructural analysis may be a useful adjunct for diagnosis.

#### *Neurologic findings and radiologic imaging of the brain*

Neurologic evaluation should be performed also on patients with presymptomatic and hepatic Wilson's disease. Consultation with a neurologist should be sought for evaluation of patients with evident neurologic symptoms before treatment or soon after treatment is initiated.

Neurologic disease may manifest as motor abnormalities with Parkinsonian characteristics of dystonia, hypertonia and rigidity, choreic or pseudosclerotic, with tremors and dysarthria. Due to the great variability of neurological signs, differences in their severity and concomitant presence of different signs in one patient, clinical description is very difficult. There is not yet a commonly accepted scale which describes neurological signs and their severity. One recent proposal is the Unified Wilson's disease Rating Scale (UWDRS) [67,68].

Magnetic resonance imaging (MRI) or computerized tomography of the brain may detect structural abnormalities in the basal ganglia [69]. The most frequent findings are an increased density on computerized tomography or hyperintensity on T2 MRI in the region of the basal ganglia. MRI may be more sensitive in detecting these lesions. Abnormal findings are not limited to this region, and other abnormalities have been described. A characteristic finding in Wilson's disease is the "face of the giant panda" sign [70,71], but is found only in a minority of patients. Besides this sign, hyperintensities in tectal-plate and central pons (CPM-like), and simultaneous involvement of basal ganglia, thalamus, and brainstem are virtually pathognomonic of Wilson's disease [72]. Significant abnormalities on brain imaging may even be present in some individuals prior to the onset of symptoms [69].

Other neuroimaging techniques as magnetic resonance spectroscopy [70] and single-photon emission computed tomography (SPECT) might be useful in detecting early brain damage in Wilson's disease, not only in the perspective of assessing and

treating motor impairment but also in better evaluating the less investigated disorders in the cognitive domain [73]. Transcranial brain parenchyma sonography (TCS) detects lenticular nucleus hyperechogenicity even when in MRI no abnormalities are observed [74], but it must be confirmed in further studies [75].

Auditory-evoked brainstem potentials are helpful to document the degree of functional impairment and the improvement by treatment [76,77].

#### *Genetic testing*

Direct molecular-genetic diagnosis is difficult because of more than 500 possible mutations; except for a few more frequent mutations, each of which is rare [78]. Furthermore, most patients are compound heterozygotes (i.e. carry two different mutations). Comprehensive molecular-genetic screening takes several months, which makes this an impractical method. Nevertheless, it is reasonable to perform molecular analysis of the *ATP7B* gene in any patient who has a provisional diagnosis of Wilson's disease, both for confirmation purposes and to facilitate the subsequent screening of family members.

By contrast, allele-specific probes allow direct identification of a mutation and this can be rapid and clinically very helpful. However, this can only be accomplished if a mutation occurs with a reasonable frequency in the population (e.g. H1069Q in Central Europe [79], -441/-427 del. in Sardinia [80,81], R778L in the Far East [82-84]). In those cases, identification of a mutation can support the diagnosis, while identification of two mutations will confirm the diagnosis. With the advancement of DNA-based diagnostics, such as the development of a single chip that is able to identify the most common mutations, these recommendations may change.

#### *Acute liver failure due to Wilson's disease*

The most challenging aspect is the diagnosis of acute liver failure due to Wilson's disease, since mortality without emergency liver transplantation is very high. Readily available laboratory tests, including alkaline phosphatase (AP), bilirubin, and serum aminotransferases, provide the most rapid and accurate method for diagnosis of acute liver failure due to Wilson's disease [85]. Combination of an AP elevation/total bilirubin elevation ratio  $<4$  and an AST:ALT ratio  $>2.2$  yielded a diagnostic sensitivity and specificity of 100% [86]. However, these findings were challenged by other authors. Therefore, these parameters should be considered in case acute Wilson's disease is suspected, but should be used in combination with other signs and symptoms suggesting Wilson's disease. The combination of clinical symptoms and the conventional Wilson's disease diagnostic parameters (ceruloplasmin, serum or urinary copper) are less sensitive and specific but important for the diagnosis [86]. The diagnosis has to be ascertained by liver biopsy if possible or at least after transplantation (hepatic copper content, mutation analysis) to enable screening of asymptomatic siblings.

#### **Family screening**

It is essential to screen the family of patients presenting with Wilson's disease because the chance of a sibling being a homozygote – and therefore developing clinical disease – is 25%. Amongst off-

## Clinical Practice Guidelines

spring, the chance is 0.5%. Although this risk is low, analysis of the *ATP7B* gene for mutations in the children of an index patient is justified given the potential devastating course of Wilson's disease. There is difficulty in diagnosing heterozygote carriers with certainty, but siblings of an index case with a documented mutation can be screened by mutational analysis.

If the mutation(s) of the index case are not detected, pedigree analysis using haplotypes based on polymorphisms surrounding the Wilson's disease gene is available. This analysis requires the identification of an index patient with the unquestionable diagnosis of Wilson's disease within the family. DNA is required from both parents. Then the haplotype, based on the pattern of dinucleotide and trinucleotide repeats around *ATP7B*, is determined in the index patient and his/her family. The inheritance of the "disease-associated" haplotypes allows determining whether they are unaffected, heterozygous, or indeed patients [78]. Genetic testing is the only reliable method to separate heterozygote from homozygote siblings.

### Treatment

A number of drugs are available for the treatment of Wilson's disease, including D-penicillamine, trientine, zinc, tetrathiomolyb-

date, and dimercaprol. Once the diagnosis has been made, treatment needs to be life-long. There is a lack of high-quality evidence to estimate the relative treatment effects of the available drugs in Wilson's disease. Therefore, multicentre prospective randomized controlled comparative trials are necessary [87].

### D-Penicillamine

The major effect of D-penicillamine in Wilson's disease is to promote the urinary excretion of copper. D-penicillamine may also act by inducing metallothionein [88]. The maintenance dose is usually 750–1500 mg/day administered in two or three divided doses. Dosing in children is 20 mg/kg/day rounded off to the nearest 250 mg and given in two or three divided doses. D-Penicillamine is best administered 1 h prior to meals, because food inhibits its absorption. Since D-penicillamine tends to interfere with pyridoxine action, supplemental pyridoxine should be provided (25–50 mg/day). D-penicillamine interferes with collagen cross-linking [89] and has some immunosuppressant actions [90,91].

Adequacy of treatment can be monitored by measuring 24-hour urinary copper excretion while on treatment. This is highest immediately after starting treatment and may exceed 16  $\mu\text{mol}$  (1000  $\mu\text{g}$ ) per 24 h at that time. For long-term treatment, the

### Recommendation 1

- Wilson's disease should be considered in any individual with liver abnormalities or neurological movement disorders of uncertain cause. Age alone should not be the basis for eliminating a diagnosis of Wilson's disease  
**GRADE II-2, A, 1**  
**AASLD Class I, Level B**
- Wilson's disease must be considered in any patient with unexplained liver disease in combination with neurological or neuropsychiatric disorders  
**GRADE II-2, A, 1**  
**AASLD Class I, Level B**
- Kayser-Fleischer rings should be sought by slit-lamp examination by a skilled examiner. The absence of Kayser-Fleischer rings does not exclude the diagnosis of Wilson's disease, even in patients with predominantly neurological disease  
**GRADE II-2, A, 1**  
**AASLD Class I, Level B**
- Neurologic evaluation and imaging of the brain, preferably by MR imaging, should be considered prior to treatment in all patients with neurologic Wilson's disease and should be part of the evaluation of any patient presenting with neurological symptoms consistent with Wilson's disease  
**GRADE II-2, B, 1**  
**AASLD Class I, Level C**
- A low serum ceruloplasmin level should be taken as evidence for the diagnosis of Wilson's disease. Borderline levels require further evaluation. Serum ceruloplasmin within the normal range does not necessarily exclude the diagnosis  
**GRADE II-2, A, 1**  
**AASLD Class I, Level B**
- Basal 24-hour urinary excretion of copper  $>1.6 \mu\text{mol}$  is typical in symptomatic patients. In children with mild hepatic disease basal 24-hour urinary excretion of copper can only be mildly elevated or may even be in the normal range. Lowering the threshold to  $>0.64 \mu\text{mol}/24 \text{ hr}$  may be useful for detecting asymptomatic patients but this will be less sensitive and will overlap with patients with other liver injury  
**GRADE II-2, B, 1**  
**AASLD Class I, Level C**
- Hepatic parenchymal copper content  $>4 \mu\text{mol}/\text{g}$  dry weight provides critical diagnostic information and should be obtained in cases where the diagnosis is not straightforward and in younger patients. In untreated patients, normal hepatic copper content ( $<0.64\text{--}0.8 \mu\text{mol}/\text{g}$  dry weight) almost always excludes a diagnosis of Wilson's disease  
**GRADE III, B, 2**  
**AASLD Class I, Level B**
- Mutation analysis with specific allelic probes or by whole-gene sequencing is currently possible and available. Specific testing for known mutations or haplotype analysis should be the primary mode for screening of first-degree relatives of patients with Wilson's disease  
**GRADE II-2, B, 1**  
**AASLD Class I, Level B**



most important sign of efficacy is a maintained clinical and laboratory improvement. Serum ceruloplasmin may decrease after initiation of treatment. Urinary copper excretion should run in the vicinity of 3–8  $\mu\text{mol}$  per 24 h on treatment. To document therapeutic efficiency, urinary copper excretion after 2 days of D-penicillamine cessation should be  $\leq 1.6 \mu\text{mol}/24 \text{ h}$ . In addition, the estimate of non-ceruloplasmin bound copper shows normalization of non-ceruloplasmin bound copper concentration with effective treatment [92]. Values of urine copper excretion  $> 1.6 \mu\text{mol}/24 \text{ h}$  after two days of D-penicillamine cessation may indicate non-adherence to therapy (in those patients non-ceruloplasmin-bound copper is elevated  $> 15 \mu\text{g/L}$ ).

D-penicillamine is rapidly absorbed from the gastrointestinal tract with a double-peaked curve for intestinal absorption [93,94]. If D-penicillamine is taken with a meal, its absorption is decreased overall by about 50%. Once absorbed, 80% of D-penicillamine circulates bound to plasma proteins. Greater than 80% of D-penicillamine excretion is via the kidneys. The excretion half-life of D-penicillamine is on the order of 1.7–7 h, but there is considerable inter-individual variation.

Numerous studies attest to the effectiveness of D-penicillamine as treatment for Wilson's disease [95–97]. In patients with symptomatic liver disease, recovery of synthetic liver function and improvement in clinical signs occur typically during the first 2–6 months of treatment, but further recovery can occur during the first year of treatment. Failure to comply with therapy leads to significant progression of liver disease and liver failure within 1–12 months following discontinuation of treatment.

In patients with neurologic Wilson's disease, improvement of symptoms is slower and may be observed even after three years [97]. Worsening of neurologic symptoms has been reported in 10–50% of patients treated with D-penicillamine during the initial phase of treatment. In a recent series, neurologic worsening occurred on all three treatments used for Wilson's disease (D-penicillamine, trientine, zinc), but mainly with D-penicillamine, where 13.8% were adversely affected [27]. Tolerability of D-penicillamine may be enhanced by starting with incremental doses, 125–250 mg/day increased by 250 mg increments every 4–7 days to a maximum of 1000–1500 mg/day in 2–4 divided dosages. Administration of doses 1500 mg per day or higher at once may lead to rapid and often irreversible neurological deterioration. Rapid re-administration of the treatment in patients who stopped it for longer time may also evoke irreversible neurological signs.

D-penicillamine is associated with numerous side effects. Severe side effects requiring the drug to be discontinued occur in approximately 30% of patients [95,98]. Early sensitivity reactions marked by fever and cutaneous eruptions, lymphadenopathy, neutropenia or thrombocytopenia, and proteinuria may occur during the first 1–3 weeks.

Significant bone marrow toxicity includes severe thrombocytopenia or total aplasia. In these conditions, D-penicillamine should be discontinued immediately. Late reactions include nephrotoxicity, usually heralded by proteinuria or the appearance of other cellular elements in the urine, for which discontinuation of D-penicillamine should be immediate. Other late reactions include a lupus-like syndrome marked by hematuria, proteinuria, and positive antinuclear antibody, and with higher dosages of D-penicillamine no longer typically used for treating Wilson's disease, Goodpasture syndrome. Dermatological toxicities reported include progeric changes in the skin and elastosis perforans serpiginosa [99], and pemphigous or pemphigoid

lesions, lichen planus, and aphthous stomatitis. Very late side effects are rare and include nephrotoxicity, myasthenia gravis [100], polymyositis, loss of taste, immunoglobulin A depression, and serous retinitis. Hepatic siderosis has been reported in treated patients with reduced levels of serum ceruloplasmin and non-ceruloplasmin bound copper [101]. Overtreatment with penicillamine may lead to a reversible sideroblastic anemia and hemosiderosis.

### Trientine

Trientine (triethylene tetramine dihydrochloride or 2,2,2-tetramine) was introduced in 1969 as an alternative to D-penicillamine. Trientine is a chelator with a polyamine-like structure chemically distinct from D-penicillamine. It lacks sulfhydryl groups and copper is chelated by forming a stable complex with the four constituent nitrogens in a planar ring. Like D-penicillamine, trientine promotes urinary copper excretion.

Few data exist about the pharmacokinetics of trientine. It is poorly absorbed from the gastrointestinal tract, and what is absorbed is metabolized and inactivated [102]. About 1% of the administered trientine and about 8% of the biotransformed trientine metabolite, acetyltrien, ultimately appear in the urine. The amounts of urinary copper, zinc and iron increase in parallel with the amount of trientine excreted in the urine [103]. The potency of trientine as copper chelator in comparison to D-penicillamine is controversial [95,104]. Trientine and D-penicillamine may mobilize different pools of body copper [105].

Typical dosages of trientine are 900–2700 mg/day in two or three divided doses, with 900–1500 mg/day used for maintenance therapy. In children, the weight-based dose is not established, but the dose generally used is 20 mg/kg/day rounded off to the nearest 250 mg, given in two or three divided doses. Trientine should be administered 1 h before or 3 h after meals. Taking it closer to meals is acceptable if this ensures compliance. Trientine tablets may not be stable for prolonged periods at high ambient temperature, which is a problem for patients travelling to warm climates.

Trientine is an effective treatment for Wilson's disease [106,107]. Trientine, while being developed for use in patients who are intolerant of penicillamine, has also been shown to be an effective initial therapy, even with patients with decompensated liver disease at the outset [108,109]. In general, adverse effects due to D-penicillamine resolve when it is substituted for trientine and do not recur during prolonged treatment with trientine.

Neurological worsening after beginning of treatment with trientine has been reported but appears less common than with D-penicillamine. Trientine also chelates iron, and co-administration of trientine and iron should be avoided because the complex with iron is toxic. A reversible sideroblastic anemia may be a consequence of overtreatment and resultant copper deficiency. Lupus-like reactions have also been reported in some Wilson's disease patients treated with trientine. However, these patients were almost all uniformly treated previously with D-penicillamine, so the true frequency of this reaction when trientine is used *de novo* is unknown.

Adequacy of treatment is monitored by measuring 24-hour urinary copper excretion (after 2 days of cessation of therapy) and by measuring non-ceruloplasmin bound copper.

## Clinical Practice Guidelines

### *Ammonium tetrathiomolybdate*

Ammonium tetrathiomolybdate (TM) is a very strong decoppering agent. TM complexes with copper; in the intestinal tract it prevents absorption, and in the circulation renders copper unavailable for cellular uptake [110]. TM can directly and reversibly down-regulate copper delivery to secreted metalloenzymes [111]. At low doses, TM removes copper from metallothionein, but at higher doses it forms an insoluble copper complex, which is deposited in the liver [112]. TM remains an experimental therapy, and it is not commercially available. As yet, clinical experience with this drug is limited. The control of free copper was prospectively studied as initial anti-copper treatment in neurologically presenting Wilson's disease patients [113]. Patients were treated for 8 weeks with TM, and thereafter with zinc. In an open-label trial, TM showed very strong control of free copper levels. In a double-blind trial, TM significantly better controlled free copper levels than trientine. On trientine, five patients worsened neurologically and this was associated with significant spikes in serum free copper levels. Other data also indicate its utility because it may less likely cause neurological deterioration [114,115]. Potential adverse effects include bone marrow depression [116], hepatotoxicity [117], and overly aggressive copper removal, which causes neurological dysfunction. TM also has anti-angiogenic effects due to its extensive decoppering effect [118].

### *Zinc*

Zinc was first used to treat Wilson's disease by Schouwink in Holland in the early 1960s [119]. Its mechanism of action is different from that of penicillamine and trientine: zinc interferes with the uptake of copper from the gastrointestinal tract. Zinc induces enterocyte metallothionein, a cysteine-rich protein that is an endogenous chelator of metals. Metallothionein has greater affinity for copper than for zinc and, thus, preferentially binds copper present in the enterocyte and inhibits its entry into the portal circulation. Once bound, the copper is not absorbed but is lost into the fecal contents as enterocytes are shed by normal turnover [120]. Because copper also enters the gastrointestinal tract from saliva and gastric secretions, zinc treatment can generate a negative balance for copper and thereby remove stored copper [121,122]. Zinc may also act by inducing levels of hepatocellular metallothionein [123,124], thus binding excess of toxic copper to prevent hepatocellular injury.

Different zinc salts (sulphate, acetate, gluconate) are used. The recommended dose is 150 mg elemental zinc/day (for children <50 kg in body weight 75 mg) administered in three divided doses, 30 min before meals. Whether a combination therapy with chelators has advantages is not yet known. However, to avoid the neutralization of zinc efficiency by chelators, different times of dosing have to be considered. The compliance with the three times per day dosage may be problematic. The zinc salt used does not make a difference with respect to efficacy but may affect tolerability. Taking the zinc medication with food interferes with its absorption [125]. Adequacy of treatment with zinc is judged by clinical and biochemical improvement and by measuring 24-hour urinary excretion of copper, which should be less than 1.6  $\mu\text{mol}$  per 24 h on stable treatment. Additionally, non-ceruloplasmin-bound copper should drop with effective treatment. Urinary excretion of zinc may be measured from time to time to check compliance.

Zinc has few side effects. Gastric irritation is a common problem and may be dependent on the salt employed. Zinc may have immunosuppressant effects and reduce leukocyte chemotaxis. Elevations in serum lipase and/or amylase may occur, without clinical or radiologic evidence of pancreatitis. Neurological deterioration is uncommon with zinc [96,126,127]. Whether high-dose zinc is safe for patients with impaired renal function is not yet established.

Most data on zinc come from uncontrolled studies of dosages ranging from 75 to 250 mg per day [87,128]. Zinc is probably less effective than chelating agents in the treatment of established Wilson's disease, although data are limited and uncontrolled [129]. Although zinc is currently reserved for maintenance treatment, it has also been used as first-line therapy, most commonly for asymptomatic or presymptomatic patients. It appears to be equally effective as D-penicillamine but better tolerated [96]. Reports of large studies in adults with Wilson's disease indicate good efficacy [122]. While zinc monotherapy appears to be effective and safe in neurologic Wilson's disease and in asymptomatic siblings, great caution is needed in patients with hepatic Wilson's disease. Hepatic deterioration has been occasionally reported when zinc was commenced and was fatal in one case [127]. Thus, exclusive monotherapy with zinc in symptomatic Wilson's liver disease is controversial. In the Netherlands, 17 symptomatic patients with Wilson's disease were treated with zinc only with a median follow-up of 14 years [128]. The outcome of exclusive zinc therapy was generally good in cases of neurologic disease. A less satisfactory outcome in hepatic disease may relate to less efficient de-coppering. Two patients with hepatic Wilson's disease progressed to a decompensated state and two patients with neurologic Wilson's disease developed symptomatic liver disease. Long-term outcomes of different treatments in 288 German and Austrian Wilson's disease patients indicated that, in the majority of patients, treatment with chelating agents or zinc salts was effective. However, there was an advantage for chelating agents to prevent hepatic deterioration [129]. In contrast, in a Polish cohort of 164 patients there were no differences in survival of patients who started therapy with zinc sulfate or D-penicillamine [38]. Current guidelines recommend that all symptomatic patients with Wilson disease should receive a chelating agent (penicillamine or trientine) [130,131]. Zinc may have a role as a first line therapy in neurological patients.

### *Other treatments*

Antioxidants, mainly vitamin E, may have a role as adjunctive treatment [132,133]. Serum and hepatic vitamin E levels have been found to be low in Wilson's disease [134–136]. Symptomatic improvement when vitamin E was added to the treatment regimen has been occasionally reported but no rigorous studies have been conducted. One study suggests no correlation of antioxidant deficiency with clinical symptoms [135].

Animal data suggest a role for amitriptyline in impending liver failure due to Wilson's disease, as it reduces the copper-induced apoptosis of liver cells, and thereby increases survival of *ATP7B*-deficient rats [137]. However, no human data are available yet.

*In vitro*, treatment with pharmacological chaperones 4-phenylbutyrate and curcumin, partially restored protein expression of most *ATP7B* mutants and might enable novel treatment strategies in Wilson's disease, by directly enhancing the protein expression of mutant *ATP7B* with residual copper export activity

[138]. Furthermore, curcumin is an ideal antioxidant and an effective scavenger of reactive oxygen species [139] and can act as a copper-chelating agent [140]. Clinical data in patients with Wilson's disease are not yet available.

*Liver transplantation*

Transplantation is frequently necessary for patients presenting with acute liver failure or decompensated cirrhosis due to Wilson's disease [141]. Because the biochemical defect resides mainly in the liver, orthotopic liver transplantation (OLT) corrects the underlying problem. Schilsky analyzed 55 transplants performed in 33 patients with decompensated cirrhosis and 21 with acute liver failure due to Wilson's disease in the United States and Europe [142]. The median survival after OLT was 2.5 years, the longest survival time after OLT was 20 years. Survival at 1 year was 79%. Nonfatal complications occurred in five patients. Fifty-one OLT were performed on 39 patients (16 pediatric, 23 adults) at the University of Pittsburgh [143]. The rate of primary graft survival was 73% and patient survival was 79%. Survival was better for those with a chronic advanced liver disease presentation (90%) than it was for those with an acute liver failure (73%) presentation. Living related donor transplantation (where the donor is an obligate hetero-

zygote) is feasible and gives excellent results [144–146]. Survival is satisfactory and appears to be better for patients having a transplant for chronic advanced liver disease than for those with acute liver failure. Overall survival is improving; the longest recorded survival is 20 years. A limited observation suggests that the neurologic symptoms of patients who need OLT may also improve as a result [145]. However, severe neurological deterioration was also observed after successful OLT [147].

**Pregnancy**

Successful treatment means that women with Wilson's disease can become pregnant [148,149]. Counseling should indicate that the likelihood of finding a homozygote amongst children is 0.5%; haplotype analysis of the partner is justified. The patient's copper status should be optimized prior to pregnancy. Although there is some concern over the teratogenicity of D-penicillamine, the risks of withdrawing treatment outweigh those of continuing it. A compilation of published case series on 161 pregnancies in 83 women with Wilson's disease (one of them after successful *in vitro* fertilization) treated with D-penicillamine during pregnancy showed 122 births with 119 normal

**Recommendation 2**

- Initial treatment for symptomatic patients with Wilson's disease should include a chelating agent (D-penicillamine or trientine). Trientine may be better tolerated  
**GRADE II-1, B, 1**  
**AASLD Class I, Level B**
- Zinc may have a role as a first line therapy in neurological patients  
**GRADE II-2, C, 2**  
**AASLD Class II, Level C**
- Treatment of presymptomatic patients or those with neurological disease on maintenance therapy can be accomplished with a chelating agent or with zinc  
**GRADE II-1, B, 1**  
**AASLD Class I, Level B**
- Treatment is lifelong and should not be discontinued, unless liver transplantation is performed  
**GRADE II-1, B, 1**  
**AASLD Class I, Level B**
- If zinc is used, careful monitoring of transaminases is needed, with changing to chelators if these laboratory parameters are increasing  
**GRADE C1**  
**AASLD Class I, Level B**
- Patients should avoid intake of foods and water with high concentrations of copper, especially during the first year of treatment  
**GRADE II-3, B, 2**  
**AASLD Class I, Level C**
- Patients with acute liver failure due to Wilson's disease should be treated with liver transplantation when the revised King's score is 11 or higher  
**GRADE II-2, B, 1**  
**AASLD Class I, Level B [41]**
- Patients with decompensated cirrhosis, unresponsive to chelation treatment, should be evaluated promptly for liver transplantation  
**GRADE II-2, B, 1**  
**AASLD Class I, Level B**
- Treatment for Wilson's disease should be continued during pregnancy, but dosage reduction is advisable for D-penicillamine and trientine  
**GRADE II-3, B, 1**  
**AASLD Class I, Level C**
- For routine monitoring, serum copper and ceruloplasmin, liver enzymes and international normalized ratio, functional parameters, complete blood count and urine analysis as well as physical and neurological examinations should be performed regularly, at least twice annually  
**GRADE II-2, B, 1**  
**AASLD Class I, Level C**
- The 24-hour urinary copper excretion on medication and after 2 days of cessation of therapy should be measured at least yearly. The estimated serum non-ceruloplasmin-bound copper may be another useful parameter to control therapy  
**GRADE II-3, B, 1**  
**AASLD Class I, Level C**

## Clinical Practice Guidelines

newborns [150]. A high abortion rate was only observed in a study from India [151].

This is also true for treatment with trientine [152] or zinc [149]. Whether the dose of a chelator should be lowered or not is based on speculations rather than data. The highest risk for fetal teratogenicity is in the first trimester, therefore lowering D-penicillamine during the first trimester was recommended with continued monitoring on the lower dosage for all trimesters [130]. Others recommended reducing the chelators to a minimal dose, i.e. 300–600 mg/day in the last trimester in order to avoid insufficient copper supply to the fetus or insufficient wound healing after Cesarean section or episiotomy [148]. Breast feeding under chelation therapy is not recommended, although there are reports that children breast fed by mothers on D-penicillamine had no problems [153].

Although contraception is an important issue, no detailed studies were performed so far. Estrogens may interfere with biliary copper excretion. In healthy women taking contraceptives, serum copper and urinary copper excretion increased [154], even corneal copper depositions were observed [155]. Many intrauterine devices contain copper. Thus, only spermicide and barrier contraceptives and progesterone-only preparations can be safely prescribed [156].

### Disclosures

The contributors to these Clinical Practice Guidelines have indicated that they have no relationships with commercial entities that might be perceived as having connection with this manuscript.

### References

- Scheinberg IH, Sternlieb I. Wilson's disease. In: Smith Jr LH, editor. Major problems in internal medicine, vol. 23. Philadelphia, PA: WB Saunders; 1984. p. 25–35.
- Gitlin JD. Wilson disease. *Gastroenterology* 2003;125:1868–1877.
- Tao TY, Gitlin JD. Hepatic copper metabolism: insights from genetic disease. *Hepatology* 2003;37:1241–1247.
- Lutsenko S, Petris MJ. Function and regulation of the mammalian copper-transporting ATPases: insights from biochemical and cell biological approaches. *J Membr Biol* 2003;191:1–12.
- Ferenci P, Czlonkowska A, Merle U, Szalay F, Gromadzka G, Yurdaydin C, et al. Late onset Wilson disease. *Gastroenterology* 2007;132:1294–1298.
- Bachmann H, Lössner J, Kühn HJ, Siegemund R. Occurrence, genetics and epidemiology of Wilson's disease in East Germany. In: Czlonkowska A, van der Hamer CJ, editors. Proc. 5th. Intern. Symposium on Wilson's disease. Technical Univ. Delft 1991. p. 121–128.
- Reilly M, Daly L, Hutchinson M. An epidemiological study of Wilson's disease in the Republic of Ireland. *J Neurol Neurosurg Psychiatry* 1993;56:298–300.
- Wilson disease mutation database. Available from: <http://www.wilsonsdisease.med.ualberta.ca/database.asp>.
- Wilson DC, Phillips MJ, Cox DW, Roberts EA. Severe hepatic Wilson's disease in preschool-aged children. *J Pediatr* 2000;137:719–722.
- Ala A, Borjigin J, Rochwarger A, Schilsky M. Wilson disease in septuagenarian siblings: raising the bar for diagnosis. *Hepatology* 2005;41:668–670.
- Czlonkowska A, Rodo M, Gromadzka G. Late onset Wilson's disease: therapeutic implications. *Mov Disord* 2008;23:897–899.
- Steindl P, Ferenci P, Dienes HP, Grimm G, Pabinger I, Madl CH, et al. Wilson's disease in patients presenting with liver disease: a diagnostic challenge. *Gastroenterology* 1997;113:212–218.
- Gow PJ, Smallwood RA, Angus PW, Smith AL, Wall AJ, Sewell RB. Diagnosis of Wilson's disease: an experience over three decades. *Gut* 2000;46:415–419.
- Sanchez-Albisua I, Garde T, Hierro L, Camarena C, Frauca E, de la Vega A, et al. A high index of suspicion: the key to an early diagnosis of Wilson's disease in childhood. *J Pediatr Gastroenterol Nutr* 1999;28:186–190.
- Cairns JE, Williams HP, Walshe JM. "Sunflower cataract" in Wilson's disease. *Br Med J* 1969;3:95–96.
- Walshe JM, Dixon AK. Dangers of non-compliance in Wilson's disease. *Lancet* 1986;12:845–847.
- Eisenbach C, Sieg O, Stremmel W, Encke J, Merle U. Diagnostic criteria for acute liver failure due to Wilson disease. *World J Gastroenterol* 2007;13:1711–1714.
- Walshe JM. The liver in Wilson's disease. In: Schiff L, Schiff ER, editors. *Diseases of the Liver*. 6th ed. Philadelphia: Lippincott; 1987. p. 1037–1050.
- Saito T. Presenting symptoms and natural history of Wilson disease. *Eur J Pediatr* 1987;146:261–265.
- Czlonkowska A, Gromadzka G, Buttner J, Chabik G. Clinical features of hemolysis, elevated liver enzymes and low platelet count syndrome in undiagnosed Wilson disease: report of two cases. *Arch Gynecol Obstet* 2009;281:129–134.
- Czlonkowska A. A study of haemolysis in Wilson's disease. *J Neurol Sci* 1972;16:303–314.
- Brewer GJ. Neurologically presenting Wilson's Disease. *CNS Drugs* 2005;19:185–192.
- LeWitt PA, Czlonkowska A. Wilson's disease. In: Lisak RP, Truong DD, Carroll WM, Bhidayasiri R, editors. *International neurology, a clinical approach*. Oxford UK: Wiley-Blackwell; 2009. p. 644–647.
- Svetel M, Potrebic A, Pekmezovic T, Tomic A, Kresojevic N, Jasic R, et al. Neuropsychiatric aspects of treated Wilson's disease. *Parkinsonism Relat Disord* 2009;15:772–775.
- Seniów J, Mroziak B, Czlonkowska A, Jędryka-Goral A. Self-rated emotional functioning of patients with neurological or asymptomatic form of Wilson's disease. *Clin Neuropsychol* 2004;17:367–373.
- Seniów J, Bąk T, Gajda J, Poniatowska R, Czlonkowska A. Cognitive functioning in neurologically symptomatic and asymptomatic forms of Wilson's disease. *Mov Disord* 2002;17:1077–1108.
- Merle U, Schaefer M, Ferenci P, Stremmel W. Clinical Presentation, diagnosis and long-term outcome of Wilson disease – a cohort study. *Gut* 2007;56:115–120.
- Ferenci P, Steindl-Munda P, Vogel W, Jessner W, Gschwantler M, Stauber R, et al. Diagnostic value of quantitative hepatic copper determination in patients with Wilson disease. *Clin Gastroenterol Hepatol* 2005;3:811–818.
- Azizi E, Eshel G, Aladjem M. Hypercalciuria and nephrolithiasis as a presenting sign in Wilson disease. *Eur J Pediatr* 1989;148:548–549.
- Nakada SY, Brown MR, Rabinowitz R. Wilson's disease presenting as symptomatic urolithiasis: a case report and review of the literature. *J Urol* 1994;152:978–979.
- Factor SM, Cho S, Sternlieb I, Scheinberg IH, Goldfischer S. The cardiomyopathy of Wilson's disease. Myocardial alterations in nine cases. *Virchows Arch [Pathol Anat]* 1982;397:301–311.
- Chu CC, Huang CC, Chu NS. Recurrent hypokalemic muscle weakness as an initial manifestation of Wilson's disease. *Nephron* 1996;73:477–479.
- Golding DN, Walshe JM. Arthropathy of Wilson's disease. Study of clinical and radiological features in 32 patients. *Ann Rheum Dis* 1977;36:99–111.
- Carpenter TO, Carnes Jr DL, Anast CS. Hypoparathyroidism in Wilson's disease. *N Engl J Med* 1983;309:873–877.
- Weizman Z, Picard E, Barki Y, Moses S. Wilson's disease associated with pancreatitis. *J Pediatr Gastroenterol Nutr* 1988;7:931–933.
- Klee JG. Undiagnosed Wilson's disease as cause of unexplained miscarriage. *Lancet* 1979;2:423.
- Tarnacka B, Rodo M, Cichy S, Czlonkowska A. Procreation ability in Wilson's disease. *Acta Neurol Scand* 2000;101:395–398.
- Czlonkowska A, Tarnacka B, Litwin T, Gajda J, Rodo M. Wilson's disease – cause of mortality in 164 patients during 1992–2003 observation period. *J Neurol* 2005;252:698–703.
- Stremmel W, Meyerrose KW, Niederau C, Hefter H, Kreuzpaintner G, Strohmeier G. Wilson's disease: clinical presentation, treatment, and survival. *Ann Intern Med* 1991;115:720–726.
- Nazer H, Ede RJ, Mowat AP, Williams R. Wilson's disease: clinical presentation and use of prognostic index. *Gut* 1986;27:1377–1381.
- Dhawan A, Taylor RM, Cheeseman P, De Silva P, Katsiyiannakis L, Mielivergani G. Wilson's disease in children: 37-year experience and revised King's score for liver transplantation. *Liver Transplant* 2005;11:441–448.

- [42] Arnon R, Annunziato R, Schilsky M, Miloh T, Willis, Sturdevant M, et al. Liver transplantation for children with Wilson disease: comparison of outcomes between children and adults. *Clin Transplant* 2011;25: E52–E60.
- [43] Cauza E, Maier-Dobersberger T, Ferenci P. Plasma ceruloplasmin as screening test for Wilson's disease. *J Hepatol* 1997;27:358–362.
- [44] Ferenci P, Caca K, Loudianos G, Mieli-Vergani G, Tanner S, Sternlieb I, et al. Diagnosis and phenotypic classification of Wilson disease. *Liver Int* 2003;23:139–142.
- [45] Nicastro E, Ranucci G, Vajro P, Vegnente A, Iorio R. Re-evaluation of the diagnostic criteria for Wilson disease in children with mild liver disease. *Hepatology* 2010;52:1948–1956.
- [46] Frieden E, Hsieh HS. Ceruloplasmin: the copper transport protein with essential oxidase activity. *Adv Enzymol* 1976;44:187–236.
- [47] Gromadzka G, Chabik G, Mendel T, Wierzchowska A, Rudnicka M, Czlonkowska A. Middle-aged heterozygous carriers of Wilson's disease do not present with significant phenotypic deviations related to copper metabolism. *J Genet* 2010;89:463–467.
- [48] Harris ZL, Klomp LW, Gitlin JD. Aceruloplasminemia: an inherited neurodegenerative disease with impairment of iron homeostasis. *Am J Clin Nutr* 1998;67:S972–S977.
- [49] Perman JA, Werlin SL, Grand RJ, Watkins JB. Laboratory measures of copper metabolism in the differentiation of chronic active hepatitis and Wilson disease in children. *J Pediatr* 1979;94:564–568.
- [50] Korman JD, Vollenberg I, Balko J, Webster J, Schiodt FV, Squires Jr RH, et al. Screening for Wilson disease in acute liver failure: a comparison of currently available diagnostic tests. *Hepatology* 2008;48:1167–1174.
- [51] Merle U, Eisenbach C, Weiss KH, Tuma S, Stremmel W. Serum ceruloplasmin oxidase activity is a sensitive and highly specific diagnostic marker for Wilson's disease. *J Hepatol* 2009;51:925–930.
- [52] Danks DM. Disorders of copper transport. In: Scriver CR, Beaudet AL, Sly WS, Valle D, editors. *The metabolic basis of inherited disease*. New York: McGraw-Hill; 1995. p. 4125–4158.
- [53] Roberts EA, Cox DW. Wilson disease. *Baillieres Clin Gastroenterol* 1998;12:237–256.
- [54] Gross Jr JB, Ludwig J, Wiesner RH, McCall JT, LaRusso NF. Abnormalities in tests of copper metabolism in primary sclerosing cholangitis. *Gastroenterology* 1985;89:272–278.
- [55] Giacchino R, Marazzi MG, Barabino A, Fasce L, Ciravegna B, Famularo L, et al. Syndromic variability of Wilson's disease in children. Clinical study of 44 cases. *Ital J Gastroenterol Hepatol* 1997;29:155–161.
- [56] Tu JB, Blackwell RQ. Studies on levels of penicillamine-induced cupriuresis in heterozygotes of Wilson's disease. *Metabolism* 1967;16:507–513.
- [57] Frommer DJ. Urinary copper excretion and hepatic copper concentrations in liver disease. *Digestion* 1981;21:169–178.
- [58] Martins da Costa C, Baldwin D, Portmann B, Lolin Y, Mowat AP, Mieli-Vergani G. Value of urinary copper excretion after penicillamine challenge in the diagnosis of Wilson's disease. *Hepatology* 1992;15: 609–615.
- [59] Muller T, Koppikar S, Taylor RM, Carragher F, Schlenck B, Heinz-Erian P, et al. Re-evaluation of the penicillamine challenge test in the diagnosis of Wilson's disease in children. *J Hepatol* 2007;47:270–276.
- [60] Song YM, Chen MD. A single determination of liver copper concentration may misdiagnose Wilson's disease. *Clin Biochem* 2000;33: 589–590.
- [61] Tanner MS. Indian childhood cirrhosis and Tyrolean childhood cirrhosis. Disorders of a copper transport gene? *Adv Exp Med Biol* 1999;448: 127–137.
- [62] Ludwig J, Moyer TP, Rakela J. The liver biopsy diagnosis of Wilson's disease. *Methods in pathology*. *Am J Clin Pathol* 1994;102:443–446.
- [63] Strohmeyer FW, Ishak KG. Histology of the liver in Wilson's disease: a study of 34 cases. *Am J Clin Pathol* 1980;73:12–24.
- [64] Strand S, Hofmann WJ, Grambihler A, Hug H, Volkmann M, Otto G, et al. Hepatic failure and liver cell damage in acute Wilson's disease involve CD95 (APO-1/Fas) mediated apoptosis. *Nat Med* 1998;4:588–593.
- [65] Goldfischer S, Sternlieb I. Changes in the distribution of hepatic copper in relation to the progression of Wilson's disease (hepatolenticular degeneration). *Am J Pathol* 1968;53:883–901.
- [66] Sternlieb I. Mitochondrial and fatty changes in hepatocytes of patients with Wilson's disease. *Gastroenterology* 1968;55:354–367.
- [67] Leinweber B, Moller JC, Scherag A, Reuner U, Gunther P, Lang CJG, et al. Evaluation of the Unified Wilson's Disease Rating Scale (UWDRS) in German patients with treated Wilson's disease. *Mov Disord* 2008;23:54–62.
- [68] Czlonkowska A, Tarnacka B, Moller JC, Leinweber B, Bandmann O, Woimant F, et al. Unified Wilson's Disease Rating Scale – a proposal for the neurological scoring of Wilson's disease patients. *Neurol Neurochir Pol* 2007;41:1–12.
- [69] van Wassenaeer-van Hall HN, van den Heuvel AG, Algra A, Hoogenraad TU, Mali WP. Wilson disease: findings at MR imaging and CT of the brain with clinical correlation. *Radiology* 1996;198:531–536.
- [70] Tarnacka B, Szeszkowski W, Gołębowski M, Czlonkowska A. MR Spectroscopy in monitoring the treatment of Wilson's disease patients. *Mov Disord* 2008;23:1560–1566.
- [71] Jacobs DA, Markowitz CE, Liebeskind DS, Galetta SL. The “double panda sign” in Wilson's disease. *Neurology* 2003;61:969.
- [72] Prashanth LK, Sinha S, Taly AB, Vasudev MK. Do MRI features distinguish Wilson's disease from other early onset extrapyramidal disorders? An analysis of 100 cases. *Mov Disord* 2010;25:672–678.
- [73] Piga M, Murru A, Satta L, Serra A, Sias A, Loi G, et al. SPECT in the diagnosis of early neurological involvement in Wilson's disease. *Eur J Nucl Med Mol Imaging* 2008;35:716–724.
- [74] Walter U, Królikowski K, Tarnacka B, Benecke R, Czlonkowska A, Dressler D. Sonographic detection of basal ganglia lesions in asymptomatic and symptomatic Wilson disease. *Neurology* 2005;64:1726–1732.
- [75] Walter U. Transcranial sonography in brain disorders with trace metal accumulation. *Int Rev Neurobiol* 2010;90:166–178.
- [76] Grimm G, Oder W, Prayer L, Ferenci P, Madl CH. Prospective follow-up study in Wilson's disease. *Lancet* 1990;336:963–964.
- [77] Grimm G, Madl CH, Katzenschlager R, Oder W, Ferenci P, Gangl A. Detailed evaluation of brain dysfunction in patients with Wilson's disease. *EEG Clin Neurophysiol* 1992;82:119–124.
- [78] Ferenci P. Wilson's disease. *Clin Gastroenterol Hepatol* 2005;3:726–733.
- [79] Ferenci P. Regional distribution of mutations of the ATP7B gene in patients with Wilson disease – impact on genetic testing. *Hum Genet* 2006;120:151–159.
- [80] Loudianos G, Dessi V, Lovicu M, Angius A, Figus AL, Lilliu F, et al. Molecular characterization of Wilson disease in the Sardinian population – evidence of a founder effect. *Hum Mutat* 1999;14:294–303.
- [81] Loudianos G, Dessi V, Lovicu M, Angius A, Altuntas B, Giacchino R, et al. Mutation analysis in patients of Mediterranean descent with Wilson disease: identification of 19 novel mutations. *J Med Genet* 1999;36:833–836.
- [82] Kim EK, Yoo OJ, Song KY, Yoo HW, Choi SY, Cho SW, et al. Identification of three novel mutations and a high frequency of the Arg778Leu mutation in Korean patients with Wilson disease. *Hum Mutat* 1998;11:275–278.
- [83] Nanji MS, Nguyen VT, Kawasoe JH, Inui K, Endo F, Nakajima T, et al. Haplotype and mutation analysis in Japanese patients with Wilson disease. *Am J Hum Genet* 1997;60:1423–1429.
- [84] Shimizu N, Nakazono H, Takeshita Y, Ikeda C, Fujii H, Watanabe A, et al. Molecular analysis and diagnosis in Japanese patients with Wilson's disease. *Pediatr Int* 1999;41:409–413.
- [85] Berman DH, Leventhal RI, Gavalier JS, Cadoff EM, Van Thiel DH. Clinical differentiation of acute Wilsonian hepatitis from other causes of hepatic failure. *Gastroenterology* 1991;100:1129–1134.
- [86] Ferenci P. Diagnosis and current therapy of Wilson's disease. *Aliment Pharmacol Ther* 2004;19:157–165.
- [87] Wiggelinkhuizen M, Tilanus ME, Bollen CW, Houwen RH. Systematic review: clinical efficacy of chelator agents and zinc in the initial treatment of Wilson disease. *Aliment Pharmacol Ther* 2009;29:947–958.
- [88] Scheinberg IH, Sternlieb I, Schilsky M, Stockert RJ. Penicillamine may detoxify copper in Wilson's disease. *Lancet* 1987;2:95.
- [89] Siegel RC. Collagen cross-linking effect of D-penicillamine on crosslinking in vitro. *J Biol Chem* 1977;252:254–259.
- [90] Lipsky PE, Ziff M. The effect of D-penicillamine on mitogen-induced human lymphocyte proliferation: synergistic inhibition by D-penicillamine and copper salts. *J Immunol* 1978;120:1006–1013.
- [91] Czlonkowska A. The influence of prolonged treatment with D-penicillamine on the immune response in Wilson's disease. *Eur J Clin Pharmacol* 1977;12:265–271.
- [92] Brewer GJ, Yuzbasiyan-Gurkan V, Lee DY, Appelman H. Treatment of Wilson's disease with zinc. VI: initial treatment studies. *J Lab Clin Med* 1989;114:633–638.
- [93] Perrett D. The metabolism and pharmacology of D-penicillamine in man. *J Rheumatol Suppl* 1981;7:41–50.
- [94] Kukovetz WR, Beubler E, Kreuzig F, Moritz AJ, Nimberger G, Werner-Breitnecker L. Bioavailability and pharmacokinetics of D-penicillamine. *J Rheumatol* 1983;10:90–94.

# Clinical Practice Guidelines

- [95] Walshe JM. Copper chelation in patients with Wilson's disease. A comparison of penicillamine and triethylene tetramine dihydrochloride. *Q J Med* 1973;42:441–452.
- [96] Czlonkowska A, Gajda J, Rodo M. Effects of long-term treatment in Wilson's disease with D-penicillamine and zinc sulphate. *J Neurol* 1996;243:269–273.
- [97] Brewer GJ, Terry CA, Aisen AM, Hill GM. Worsening of neurologic syndrome in patients with Wilson's disease with initial penicillamine therapy. *Arch Neurol* 1987;44:490–493.
- [98] Medici V, Trevisan CP, D'Inca R, Barollo M, Zancan L, Fagioli S, et al. Diagnosis and management of Wilson's disease: results of a single center experience. *J Clin Gastroenterol* 2006;40:936–941.
- [99] Becuwe C, Dalle S, Ronger-Savle S, Skowron F, Balme B, Kanitakis J, et al. Elastosis perforans serpiginosa associated with pseudo-pseudoxanthoma elasticum during treatment of Wilson's disease with penicillamine. *Dermatology* 2005;210:60–63.
- [100] Czlonkowska A. Myasthenia syndrome during penicillamine treatment. *Brit Med J* 1975;2:726–727.
- [101] Shiono Y, Wakusawa S, Hayashi H, Takikawa T, Yano M, Okada T, et al. Iron accumulation in the liver of male patients with Wilson disease. *Am J Gastroenterol* 2001;96:3147–3151.
- [102] Walshe JM. Treatment of Wilson's disease with trientine (triethylene tetramine) dihydrochloride. *Lancet* 1982;1:643–647.
- [103] Kodama H, Murata Y, Iitsuka T, Abe T. Metabolism of administered triethylene tetramine dihydrochloride in humans. *Life Sci* 1997;61:899–907.
- [104] Borthwick TR, Benson GD, Schugar HJ. Copper chelating agents. A comparison of cupruritic responses to various tetramines and D-penicillamine. *J Lab Clin Med* 1980;95:575–580.
- [105] Sarkar B, Sass-Kortsak A, Clarke R, Laurie SH, Wei P. A comparative study of in vitro and in vivo interaction of D-penicillamine and triethylene-tetramine with copper. *Proc R Soc Med* 1977;70:13–18.
- [106] Walshe JM. The management of Wilson's disease with triethylene tetramine 2HCl (Trien 2HCl). *Prog Clin Biol Res* 1979;34:271–280.
- [107] Scheinberg IH, Jaffe ME, Sternlieb I. The use of trientine in preventing the effects of interrupting penicillamine therapy in Wilson's disease. *N Engl J Med* 1987;317:209–213.
- [108] Saito H, Watanabe K, Sahara M, Mochizuki R, Edo K, Ohyama Y. Triethylene-tetramine (trien) therapy for Wilson's disease. *Tohoku J Exp Med* 1991;164:29–35.
- [109] Santos Silva EE, Sarles J, Buts JP, Sokal EM. Successful medical treatment of severely decompensated Wilson disease. *J Pediatr* 1996;128:285–287.
- [110] Brewer GJ, Dick RD, Johnson V, Wang Y, Yuzbasiyan-Gurkan V, Kluijn K, et al. Treatment of Wilson's disease with ammonium tetrathiomolybdate: I. Initial therapy in 17 neurologically affected patients. *Arch Neurol* 1994;51:545–554.
- [111] Alvarez HM, Xue Y, Robinson CD, Canalizo-Hernández MA, Marvin RG, Kelly RA, et al. Tetrathiomolybdate inhibits copper trafficking proteins through metal cluster formation. *Science* 2010;327:331–334.
- [112] Ogra Y, Suzuki KT. Targeting of tetrathiomolybdate on the copper accumulating in the liver of LEC rats. *J Inorg Biochem* 1998;70:49–55.
- [113] Brewer GJ, Askari F, Dick RB, Sitterly J, Fink JK, Carlson M, et al. Treatment of Wilson's disease with tetrathiomolybdate: V. Control of free copper by tetrathiomolybdate and a comparison with trientine. *Transl Res* 2009;154:70–77.
- [114] Brewer GJ, Hedera P, Kluijn KJ, Carlson M, Askari F, Dick RB, et al. Treatment of Wilson disease with ammonium tetrathiomolybdate. III: initial therapy in a total of 55 neurologically affected patients and follow-up with zinc therapy. *Arch Neurol* 2003;60:379–385.
- [115] Brewer GJ, Askari F, Lorincz MT, Carlson M, Schilsky M, Kluijn KJ, et al. Treatment of Wilson disease with ammonium tetrathiomolybdate. IV: comparison of tetrathiomolybdate and trientine in a double-blind study of treatment of the neurologic presentation of Wilson disease. *Arch Neurol* 2006;63:521–527.
- [116] Karunajeewa H, Wall A, Metz J, Grigg A. Cytopenias secondary to copper depletion complicating ammonium tetrathiomolybdate therapy for Wilson's disease. *Aust NZ J Med* 1998;28:215–216.
- [117] Medici V, Trevisan CP, Bigotto MA, D'Inca R, Martines D, Dal Pont E, et al. Adverse reaction after tetrathiomolybdate treatment for Wilson's disease: a case report. *Mov Disord* 2006;21:2030–2032.
- [118] Pan Q, Kleer CG, van Golen KL, Irani J, Bottema KM, Bias C, et al. Copper deficiency induced by tetrathiomolybdate suppresses tumor growth and angiogenesis. *Cancer Res* 2002;62:4854–4859.
- [119] Hoogenraad TU, Koevoet R, de Ruyter Korver EG. Oral zinc sulphate as long-term treatment in Wilson's disease (hepatolenticular degeneration). *Eur Neurol* 1979;18:205–211.
- [120] Brewer GJ, Yuzbasiyan-Gurkan V, Young AB. Treatment of Wilson's disease. *Semin Neurol* 1987;7:209–220.
- [121] Brewer GJ, Hill GM, Prasad AS, Cossack ZT, Rabbani P. Oral zinc therapy for Wilson's disease. *Ann Intern Med* 1983;99:314–319.
- [122] Hoogenraad TU. Zinc treatment of Wilson's disease. *J Lab Clin Med* 1998;132:240–241.
- [123] Cousins RJ. Absorption, transport and hepatic metabolism of copper and zinc: special reference to metallothionein and ceruloplasmin. *Physiol Rev* 1985;65:238–309.
- [124] Schilsky M, Blank RR, Czaja MJ, Scheinberg IH, Stockert RJ, Sternlieb I. Hepatocellular copper toxicity and its attenuation by zinc. *J Clin Invest* 1989;84:1562–1568.
- [125] Pecoud A, Dozel F, Schelling JL. The effect of foodstuffs on the absorption of zinc sulfate. *Clin Pharmacol Ther* 1975;17:469–474.
- [126] Ferenci P. Zinc treatment of Wilson's disease. In: Kruse-Jarres JD, Schölmicher J, editors. *Zinc and diseases of the digestive tract*. Lancaster: Kluwer Academic Publishers;1997. p. 117–124.
- [127] Walshe JM, Munro NA. Zinc-induced deterioration in Wilson's disease aborted by treatment with penicillamine, dimercaprol, and a novel zero copper diet. *Arch Neurol* 1995;52:10–11.
- [128] Linn FH, Houwen RH, van Hattum J, van der Kleij S, van Erpecum KJ. Long-term exclusive zinc monotherapy in symptomatic Wilson disease: experience in 17 patients. *Hepatology* 2009;50:1442–1452.
- [129] Weiss KH, Gotthardt D, Klemm D, Merle U, Ferenci-Foerster D, Schaefer M, et al. Zinc monotherapy is not as effective as chelating agents in treatment of Wilson disease. *Gastroenterology* 2011;140:1189–1198.
- [130] Roberts EA, Schilsky ML. AASLD practice guidelines: a practice guideline on Wilson disease. *Hepatology* 2008;47:2094–2108.
- [131] Walshe JM, Yealland M. Chelation treatment of neurological Wilson's disease. *Q J Med* 1993;86:197–204.
- [132] Fryer MJ. Potential of vitamin E as an antioxidant adjunct in Wilson's disease. *Med Hypotheses* 2009;73:1029–1030.
- [133] Shen L, Ji HF. Adjunctive vitamin E treatment in Wilson disease, suggestions for future trials. *Hepatology* 2010;51:1864.
- [134] von Herbay A, de Groot H, Hegi U, Stremmel W, Strohmeier G, Sies H. Low vitamin E content in plasma of patients with alcoholic liver disease, hemochromatosis and Wilson's disease. *J Hepatol* 1994;20:41–46.
- [135] Sinha S, Christopher R, Arunodaya GR, Prashanth LK, Gopinath G, Swamy HS, et al. Is low serum tocopherol in Wilson's disease a significant symptom? *J Neurol Sci* 2005;228:121–123.
- [136] Sokol RJ, Twedt D, McKim Jr JM, Devereaux MW, Karrer FM, Kam I, et al. Oxidant injury to hepatic mitochondria in patients with Wilson's disease and Bedlington terriers with copper toxicosis. *Gastroenterology* 1994;107:1788–1798.
- [137] Lang PA, Schenck M, Nicolay JP, Becker JU, Kempe DS, Lupescu A, et al. Liver cell death and anemia in Wilson disease involve acid sphingomyelinase and ceramide. *Nature Med* 2007;13:164–170.
- [138] van den Berghe PV, Stapelbroek JM, Krieger E, de Bie P, van de Graaf SF, de Groot RE, et al. Reduced expression of ATP7B affected by Wilson disease-causing mutations is rescued by pharmacological folding chaperones 4-phenylbutyrate and curcumin. *Hepatology* 2009;50:1783–1795.
- [139] Sreejayan, Rao MN. Nitric oxide scavenging by curcuminoids. *J Pharm Pharmacol* 1997;49:105–107.
- [140] Barik A, Mishra B, Shen L, Mohan H, Kadam RM, Dutta S, et al. Evaluation of a new copper(II)-curcumin complex as superoxide dismutase mimic and its free radical reactions. *Free Radic Biol Med* 2005;39:811–822.
- [141] Khanna A, Jain A, Eghtesad B, Rakela J. Liver transplantation for metabolic liver diseases. *Surg Clin North Am* 1999;79:153–162.
- [142] Schilsky ML, Scheinberg IH, Sternlieb I. Liver transplantation for Wilson's disease: indications and outcome. *Hepatology* 1994;19:583–587.
- [143] Bellary S, Hassanein T, Van Thiel DH. Liver transplantation for Wilson's disease. *J Hepatol* 1995;23:373–381.
- [144] Yoshitoshi EY, Takada Y, Oike F, Sakamoto S, Ogawa K, Kanazawa H, et al. Long-term outcomes for 32 cases of Wilson's disease after living-donor liver transplantation. *Transplantation* 2009;87:261–267.
- [145] Schumacher G, Platz KP, Mueller AR, Neuhaus R, Luck W, Langrehr JM, et al. Liver transplantation in neurologic Wilson's disease. *Transplant Proc* 2001;33:1518–1519.
- [146] Cheng F, Li GQ, Zhang F, Li XC, Sun BC, Kong LB, et al. Outcomes of living-related liver transplantation for Wilson's disease: a single-center experience in China. *Transplantation* 2009;87:751–757.
- [147] Litwin T, Gromadzka G, Czlonkowska A. Neurological presentation of Wilson's disease in a patient after liver transplantation. *Mov Disord* 2008;23:743–746.

- [148] Scheinberg IH, Sternlieb I. Pregnancy in penicillamine-treated patients with Wilson's disease. *N Engl J Med* 1975;293:1300–1302.
- [149] Brewer GJ, Johnson VD, Dick RD, Hedera P, Fink JK, Kluin KJ. Treatment of Wilson's disease with zinc XVII: treatment during pregnancy. *Hepatology* 2000;31:364–370.
- [150] Ferenci P. Wilson's Disease. In: Bacon B, ÓGrady JG, DiBisceglie A, Lake JR, editors. *Comprehensive clinical hepatology*. [Chapter 24]. Maryland Heights, Miss. USA: Elsevier Mosby; 2005. p. 351–367.
- [151] Sinha S, Taly AB, Prashanth LK, Arunodaya GR, Swamy HS. Successful pregnancies and abortions in symptomatic and asymptomatic Wilson's disease. *J Neurol Sci* 2004;217:37–40.
- [152] Walshe JM. The management of pregnancy in Wilson's disease treated with trientine. *Q J Med* 1986;58:81–87.
- [153] Messner U, Günter HH, Niesert S. Wilson disease and pregnancy. Review of the literature and case report. *Z Geburtshilfe Neonatol* 1998;202:77–79.
- [154] Rubinfeld Y, Maor Y, Simon D, Modai D. A progressive rise in serum copper levels in women taking oral contraceptives: a potential hazard? *Fertil Steril* 1979;32:599–601.
- [155] Garmizo G, Frauens BJ. Corneal copper deposition secondary to oral contraceptives. *Optom Vis Sci* 2008;85:E802–E807.
- [156] Haimov-Kochman R, Ackerman Z, Anteby EY. The contraceptive choice for a Wilson's disease patient with chronic liver disease. *Contraception* 1997;56:241–244.
- [157] Walshe JM. Wilson's disease presenting with features of hepatic dysfunction: a clinical analysis of eighty-seven patients. *Q J Med* 1989;70:253–263.
- [158] Scott J, Gollan JL, Samourian S, Sherlock S. Wilson's disease, presenting as chronic active hepatitis. *Gastroenterology* 1978;74:645–651.
- [159] Guyatt GH, Oxman AD, Vist GE, Kunz R, Falck-Ytter Y, Alono-Coello P, et al. GRADE: an emerging consensus on rating quality of evidence and strength of recommendations. *BMJ* 2008;336:924–926.