

- ***The role of endoscopy in the evaluation and management of patients with solid pancreatic neoplasia***

Presented by Dr.neda rad, fellowship of Taleghani hospital

- Patients with suspected solid pancreatic neoplasia may present with obstructive jaundice, abdominal pain, anorexia, weight loss, acute pancreatitis, new onset or poorly controlled diabetes, or steatorrhea. The physical examination can include findings such as jaundice, muscle wasting, pertinent skin lesions, palpable adenopathy, hepatomegaly, or masses.

- Occasionally these lesions will be identified coincidentally on surveillance abdominal imaging tests or during evaluation of unrelated abdominal pain. Elevations in routine or diagnostic liver enzyme testing, especially increased levels of bilirubin and alkaline phosphatase, may lead to a diagnosis of cholestasis due to biliary obstruction localized to the head of the pancreas.

- Conversely, patients with pancreatic malignancy in the body and tail typically present with more advanced-stage disease and normal liver biochemistry results because of the absence of biliary obstruction.

- The utility of serum markers such as CA 19-9 in patients with suspected pancreatic neoplasia is controversial. CA19-9 levels are elevated in the peripheral blood of the majority of patients with pancreatic cancer, but this finding does not achieve the performance required for either early detection or diagnosis, because of the potential for both false positive and false negative results.

- However, despite its shortcomings, CA 19-9 is the only U.S. Food and Drug Administration approved biomarker recommended for use in the routine management of pancreatic ductal adenocarcinoma. It has been used for prognosis and as a marker of disease burden (ie, recurrence or disease progression).⁵

- Suspicion of pancreatic neoplasia should prompt additional investigation with chest and abdominal imaging studies to assist in diagnosis, staging, and therapeutic planning.

TABLE 2. Pancreatic neoplasia

Primary
Pancreatic neoplasia
Malignant
Exocrine
Pancreatic adenocarcinoma (solid and/or cystic)
Acinar cell
Endocrine
Neuroendocrine tumors
Benign
Exocrine
Solid pseudopapillary tumor
Cystic neoplasms of the pancreas
Endocrine
Neuroendocrine tumors
Metastatic
Unclassified
Lymphoma

- The endoscopic evaluation of solid pancreatic tumors is directed toward detection, staging, and obtaining a correct tissue diagnosis in cases that are not going directly to surgery. Correct pathologic diagnosis in rare cases of lymphoma or autoimmune pancreatitis mimicking pancreatic cancer might preclude surgery in these patients.

Radiologic modalities

- **Transabdominal US.** Transabdominal US (TUS) may suggest biliary obstruction by demonstrating biliary ductal dilation. It also may identify the presence of obvious liver metastases. TUS is operator dependent and has a poor sensitivity for detecting small neoplasms of the pancreatic head.

- However, recent advances such as color-power Doppler US, contrast-enhanced US, harmonic imaging, and 3-dimensional (3-D) US may improve the utility of this modality in the staging of pancreatic cancer. Contrast-enhanced US is useful in evaluating the realtime vascularity of various pancreatic masses, which may aid in the differential diagnosis of pancreatic mass lesions.

- Nonetheless, more information regarding staging and extent of disease, and possible nodal or vascular involvement, can be obtained with other imaging modalities.

- **CT and magnetic resonance imaging.** CT is the most widely available modality for the noninvasive assessment of tumor resectability and detection of liver metastases, information that allows further planning of tissue confirmation and palliative care.

- CT imaging has significantly improved with the introduction of multiple-detector CT, which allows high-resolution 3-D imaging and multiplanar image reconstruction. Faster injection of iodinated contrast medium and precisely timed post-injection image acquisition are techniques that have improved the sensitivity of CT for detecting pancreatic adenocarcinoma.

- CT is insensitive for the detection of pancreatic lesions <2 cm in size. It is very sensitive for identification of larger tumors and can accurately stage and assess resectability by detection of tumor extension, liver metastases, and invasion of vascular structures.

- If CT findings highly suggest a resectable pancreatic carcinoma, and the patient is deemed to be an operative candidate, it may be reasonable to refer the patient directly for surgical resection (eg, pancreaticoduodenectomy).

- CT-guided biopsy of pancreatic masses has a reported sensitivity up to 95%.^{21,22} However, needle-track seeding has been reported with this technique. In 1 study, peritoneal carcinomatosis was observed to be significantly more common among patients with pancreatic masses who underwent percutaneous sampling rather than EUS-guided biopsy (16.3% vs 2.2%, respectively, $P < .025$).²

- The role of magnetic resonance imaging (MRI) for evaluation of pancreatic malignancy continues to evolve. Although CT historically has been more sensitive than MRI at the detection of pancreatic carcinoma, a recent study concluded that MRI was superior to CT for tumor detection.

- MRI may reliably detect smaller, noncontour-deforming tumors compared with CT. MRI also more accurately detects and characterizes smaller hepatic metastases.

- In 1 study that compared the diagnostic performance (detection, local staging) of multiphasic 64-detector CT with gadobenate dimeglumine-enhanced 3.0-T MRI in patients suspected of having pancreatic cancer, both CT and MRI were found to be equally suited for detecting and staging pancreatic cancer. Therefore, the choice of imaging modality for detection and staging of pancreatic cancer depends on test availability and local expertise.

- **positron emission tomography and integrated PET/CT.** Positron emission tomography (PET) is a technique based on differential metabolic activity of neoplastic and nonneoplastic tissue. It most often uses 18fluorodexyglucose (18FDG), a tracer of glucose metabolism, as an adjunct to conventional imaging. PET may be used for the diagnosis and staging of pancreatic cancer but also for postoperative surveillance to detect local and distant recurrence or metastases.

- The development and standardization of PET integrated with CT technology (PET/CT) has dramatically enhanced the diagnostic capabilities of these 2 modalities for pancreatic cancer, particularly for masses .

- A recent meta-analysis of 51 studies involving 3857 patients compared the diagnostic performance of 18FDG PET alone, 18FDG PET/CT, and EUS for diagnosing pancreatic cancer. The study concluded that the pooled sensitivity estimate for 18FDG PET/CT of 90.1% (95% confidence interval [CI], 85.5%-93.6%) was significantly greater than that of 18FDG PET alone (88.4%; 95% CI, 86.3%-90.3%) or EUS (81.2%; 95% CI, 78.7%-83.5%; $P < .001$ for all comparisons).

- However, EUS had the highest specificity for diagnosing pancreatic cancer (93.2%; 95% CI, 91.7%-94.5%) and was significantly better than 18FDG PET (83.1%; 95% CI, 79.6%-86.3%) and 18FDG PET/CT (80.1%; 95% CI, 73.1%-86.0%; $P < .001$ for all comparisons).

- **Endoscopic modalities EUS.** Although EUS is more operator dependent compared with CT and MRI, it is the most sensitive test in expert hands to detect pancreatic mass lesions or pancreatic adenocarcinoma, particularly when lesions are equivocal by CT or <2 cm in size.

- In a systematic review of 9 studies and 678 patients, DeWitt et al concluded that EUS was more sensitive than CT for the detection of pancreatic adenocarcinoma (91%- 100% vs 53%-91%), but the 2 studies were equivalent for loco-regional tumor staging.

- EUS also allows tissue acquisition for pathology diagnosis, but sampling may not be necessary before surgery in resectable tumors.

- However, in some situations, a nonoperative pathology diagnosis in patients with otherwise resectable lesions may be desired. For example, endoscopic tissue diagnosis is helpful for the diagnosis of medically treated conditions that may mimic neoplasms or tumors such as autoimmune pancreatitis or lymphoma, for permitting patient enrollment into a neoadjuvant chemotherapy protocol, or for preoperative patient counseling.

- EUS-guided tissue sampling can be performed by FNA (EUS-guided FNA [EUS-FNA]) or by EUS-guided fine-needle core biopsy (EUS-FNB). EUS-FNA has a sensitivity and specificity of up to 95% and 100%, respectively and is the preferred method for making a definitive cytology diagnosis of a pancreatic mass, even when results of other biopsy methods are negative or equivocal for malignancy.

- This approach has been shown to be cost-effective as well. Immediate evaluation and feedback from an on-site cytopathologist during sampling increases diagnostic yield by 10% to 15%. Although EUS-FNA with cytopathology usually is adequate for a diagnosis of adenocarcinoma and neuroendocrine tumors (NETs), it may not provide sufficient material for complete histologic examination for diseases such as lymphoma, well-differentiated carcinoma, or autoimmune pancreatitis.

- EUS-FNB has not been shown to be superior to EUS-FNA for determining the etiology of pancreatic masses but should be considered if EUS-FNA is nondiagnostic and a histologic diagnosis is required. FNB is technically difficult for sampling of pancreatic head masses because of the stiffness of the needle and the acute angulation of the endoscope required for biopsy from this location.

- More-flexible needles have been developed recently that may circumvent this problem and allow better transduodenal sampling of pancreatic head masses that require core tissue to better determine the nature of the lesion.

- Potential adverse events from EUS-guided sampling of pancreatic masses include a 0.5% to 2% risk of pancreatitis or bleeding. Tumor seeding with EUS-FNA has been reported, but the risk appears to be exceedingly small, and reports are currently limited to isolated cases.

- It remains unclear whether the risk of tumor seeding with EUS-FNA is related to the number of passes required to obtain adequate diagnostic samples.

- A recent study by Beane et al showed that preoperative EUS-FNA is not associated with adverse perioperative or long-term outcomes in patients undergoing distal pancreatectomy for solid neoplasms of the pancreas. Another study that evaluated survival after pancreatic cancer surgery in patients with and without prior EUS-FNA showed that survival was slightly better in the EUS-FNA group, although results were not statistically significant.

- EUS traditionally has been performed before ERCP with stent placement because of the potential negative impact of the biliary stent on the accuracy of EUS staging. However, recent studies suggest that staging accuracy may not be compromised by an indwelling stent. EUS before ERCP also may identify unresectable pancreatic adenocarcinoma and help triage patients to biliary selfexpandable metal stent (SEMS) placement at subsequent ERCP.

- In patients with pancreatic cancer–related pain, EUSguided celiac plexus neurolysis (EUS-CPN) may be considered. Performed via a transgastric approach, EUS-CPN attempts to ablate the neurons of the celiac ganglia through the injection of cytolytic agents such as alcohol or phenol. CPN is the preferred therapy in patients with cancer related pain.

- A meta-analysis by Kaufman et al of 5 studies including 199 patients found that EUS-CPN was effective in alleviating abdominal pain in 72% of patients. A double-blind, controlled trial found that early EUS-CPN reduces pain and may moderate morphine consumption in patients with newly diagnosed, painful, inoperable pancreatic cancer. CPN can cause transient diarrhea, hypotension, and abdominal pain .

- Although CPN is a very effective and safe procedure, major adverse events including reversible and permanent paralysis, organ puncture, and gastric necrosis have been described.

- EUS-guided fiducial placement has been used to aid in image-guided radiation therapy. Fiducials can be placed with either 19-gauge or 22-gauge needles. Recently, preloaded fiducials on a 22-gauge needle have become commercially available.

- The procedure is very similar in concept to EUS-guided FNA and can be performed with or without fluoroscopy. The rate of adverse events from fiducial placement is comparable to that of EUS-FNA of the pancreas. Adverse events include mild pancreatitis, minor bleeding, and fiducial migration, requiring a repeat procedure.

- EUS-guided fine-needle tattooing (EUS-FNT) has been reported to aid in the localization of pancreatic tumors in patients undergoing laparoscopic distal pancreatectomy. This is particularly helpful for cases in which abdominal imaging does not detect a lesion. In one study, the carbon particle tattoo injected by EUS-FNT was durable and visible in all 13 cases that underwent preoperative EUS-FNT.

- **ERCP**. ERCP findings suggestive of a pancreatic head malignancy include strictures of both the bile and pancreatic ducts with upstream dilation (ie, double duct sign).

- EUS has largely supplanted ERCP for the diagnosis of pancreatic head adenocarcinoma, and preoperative ERCP does not add further staging information beyond what may be obtained with EUS. ERCP has little value in the diagnosis or palliation of patients with adenocarcinoma of the pancreatic body and/or tail.

- Preoperative ERCP may also result in adverse events, thus delaying or complicating operative interventions or the potential for curative resection. Even in the absence of adverse events from ERCP, several studies suggest that the rate of postoperative adverse events after pancreaticoduodenectomy is higher when a preoperative ERCP is performed (with or without stent placement).

- However, preoperative ERCP with biliary drainage should be performed in patients with cholangitis, severe pruritus, or possible delay in operative resection or in those patients in whom neoadjuvant chemotherapy and radiation are being considered.

- ERCP with pancreatic duct brush cytology and biopsy may be required for evaluation of suspicious pancreatic duct strictures or after nondiagnostic EUS-FNA. The specificity of brush cytology and biopsy approaches 100%; however, the sensitivity is only 15% to 50% for brush cytology and 33% to 50% for biopsy.

- Palliation of symptomatic obstructive jaundice among patients with unresectable disease can be achieved with ERCP and biliary stent placement, percutaneous stent placement, or surgical bypass.⁸⁸ Although plastic stents are less expensive than SEMs, these stents occlude after a median of 3 to 6 months because of deposition of bacterial biofilm, thus increasing the risk of recurrent jaundice and cholangitis.

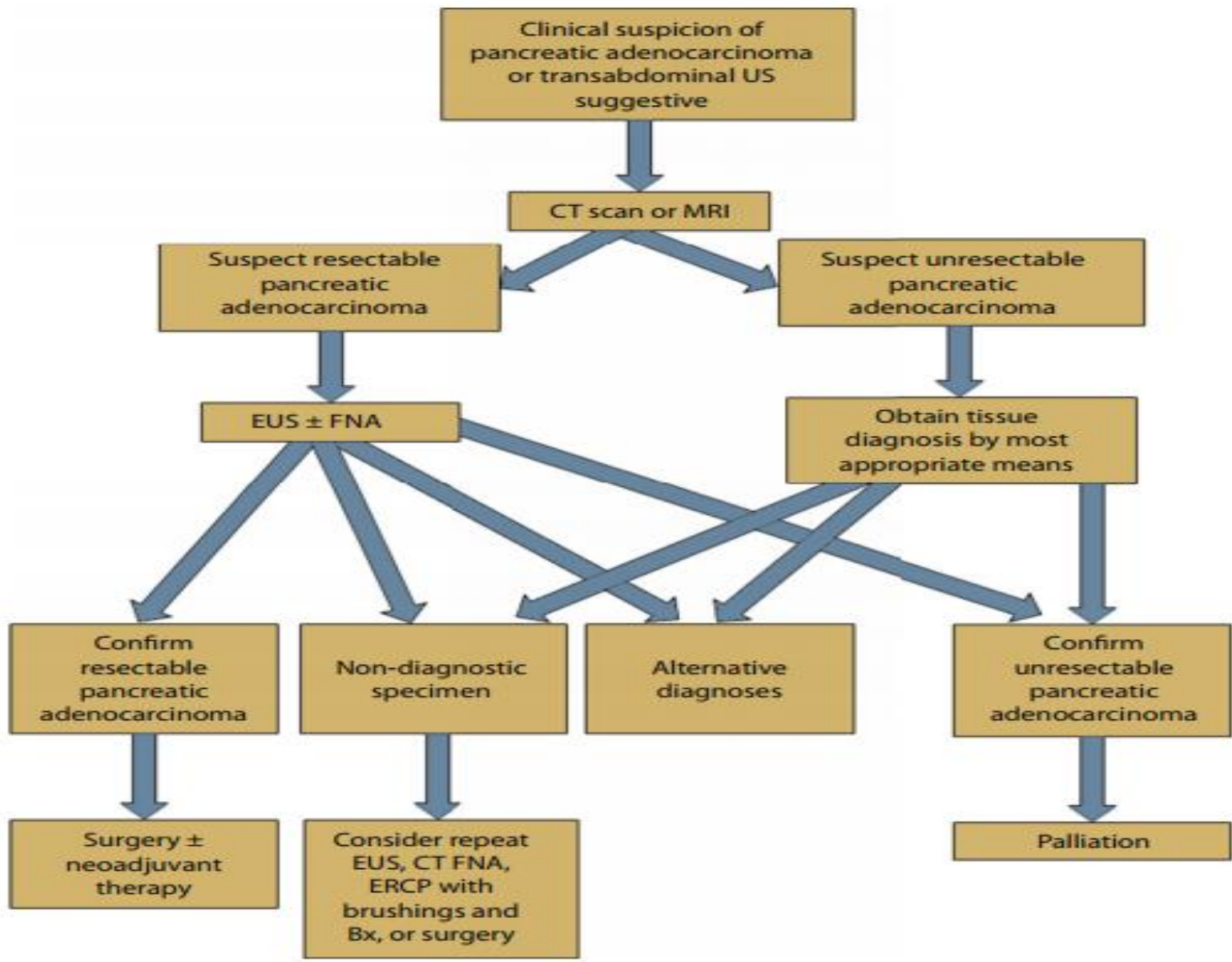
- Data regarding the utility of placing multiple plastic stents to prolong patency in malignant biliary strictures are lacking. Biliary SEMSs may be covered or uncovered and have a significantly longer patency rate than do plastic stents. Although it has been suggested that the use of SEMSs be reserved for patients whose estimated survival is >3 to 6 months, a recent Cochrane review concluded that the choice of stent type in these patients should be individualized.

- A more recent study of 30 patients with metastatic pancreatic cancer and biliary obstruction randomized to surgical bypass or ERCP with SEMSs found that endoscopic drainage is less expensive and provides better quality of life.

- When ERCP is unsuccessful, interventional EUS techniques or percutaneous transhepatic cholangiography with stent placement can be considered where local expertise is available.

- Patients with unresectable pancreatic adenocarcinoma who develop malignant gastric outlet obstruction can be palliated through surgical bypass, percutaneous or endoscopic decompression using gastrostomy, or endoscopic gastroduodenal SEMS placement.

- Endoscopic gastroduodenal SEMS placement can be delivered either through or alongside the endoscope with fluoroscopic guidance .



NEUROENDOCRINE TUMORS (NETS) OF THE PANCREAS

- NETs of the pancreas are rare tumors thought to arise from neuroendocrine cells within pancreatic islets. The majority of pancreatic NETs are sporadic, but about 10% to 30% of patients with NETs have multiple endocrine neoplasia type 1 syndrome.

- The majority (50%-60%) of pancreatic NETs are nonfunctioning. Nonfunctioning NETs present with a pancreatic mass, and their presentation may mimic that of adenocarcinoma, although biliary obstruction is uncommon.

- Functioning NETs are classified according to the hormone secreted by the tumor and include insulinomas, gastrinomas, VIPomas, glucagonomas, and somatostatinomas, and they may present with their associated hormone syndromes .

- Pancreatic NETs are staged by the same TNM staging system used for exocrine pancreatic tumors . Although NETs often are detected incidentally by cross-sectional imaging, EUS also plays an important role in detection and confirmation of the diagnosis.

- Radiologic modalities. The TUS appearance of pancreatic NETs is typically a well-defined, hypoechoic, round mass that may demonstrate a hyperechoic halo or may distort the gland. Pancreatic NETs are most commonly detected on CT as small solid masses, but, rarely, they can be cystic.

- On before-contrast images, pancreatic NETs are isodense with the pancreatic parenchyma but enhance significantly after contrast, particularly in the arterial phase. This is in contrast to adenocarcinoma, which typically appears hypointense after contrast. On MRI, pancreatic NETs exhibit low signal intensity on T1-weighted sequences and high signal intensity on T2-weighted sequences.

- After gadolinium administration, pancreatic NETs enhance homogeneously, although larger tumors may be heterogeneous, and rim enhancement may be seen. Somatostatin receptor scintigraphy can be a useful tool to localize NETs and to detect metastases.

- Endoscopic modalities EUS. Pancreatic NETs typically appear solid, hypoechoic, and homogenous, with distinct margins on EUS. Rarely they may be cystic and confused with other cystic lesions of the pancreas. EUS is superior to TUS, CT, MRI, and somatostatin receptor scintigraphy for the localization of NETs, with a sensitivity of 82% to 93%.¹⁰⁵

- Despite improved cross-sectional imaging, EUS remains superior to CT for detection of pancreatic NETs, particularly for insulinomas. EUS also permits tissue acquisition, which is particularly useful in small or nonfunctioning tumors.

- ERCP. ERCP does not have a primary role in the diagnosis of pancreatic NETs. For rare lesions that compress the pancreatic duct or cause biliary obstruction, ERCP may have an important therapeutic role.

SOLID PSEUDOPAPILLARY TUMORS (SPTs)

- SPTs of the pancreas are rare tumors that predominantly affect young women in the third decade of life. Unlike pancreatic adenocarcinoma, these tumors have a low malignant potential, and usually surgery is curative. Rarely, SPTs may develop in extrapancreatic locations.

- The most common presentation is pain or a palpable abdominal mass, but other nonspecific symptoms such as nausea and vomiting may occur. SPTs are often large, with a median size of 6 cm to 7 cm, and frequently they are discovered incidentally.

- Although radiologic and endoscopic imaging are important in the evaluation of these tumors, the diagnosis of SPTs can be difficult. In the largest series of SPTs reported to date, only 52 of 718 cases (7%) had a preoperative diagnosis confirmed by biopsy.

- Radiologic modalities On TUS, SPTs appear as well-defined, heterogeneous, solid masses that may contain areas of cystic degeneration or hemorrhage. Data are lacking regarding the sensitivity and specificity of TUS for diagnosing SPTs. The typical CT appearance of an SPT consists of a large, wellcircumscribed, heterogeneous mass with solid and cystic components. Areas of internal hemorrhage and a capsule also may be visualized.

- These tumors are typically avascular or hypovascular. The overall appearance of an SPT on MRI is similar to that of CT, but MRI allows better identification of cystic portions or hemorrhage within the tumor.

- Endoscopic modalities EUS. In a retrospective, multicenter study of 28 cases, EUS-FNA confirmed the diagnosis of SPT in 75% (21/28). Sonographically, SPTs were echo poor and solid in 50% (14/28), mixed solid and cystic in 39% (11/28), and cystic alone in 11% (3/28).

- Irregular calcification was seen in 21% (6/28). Other reports have supported the role of EUS-FNA in the diagnosis of SPTs.

- Preoperative sampling of SPTs may not be necessary because both a positive diagnosis and nondiagnostic specimen do not change planned surgical management .

METASTATIC DISEASE

- Metastases to the pancreas are rare and do not show predilection for any region of the pancreas. The most common metastasis to the pancreas is renal cell carcinoma, but a variety of other cancers including melanoma, breast, lung, and colorectal cancers have been reported.

- There is often a long delay between the original diagnosis and the appearance of pancreatic metastasis, and multiple metastases may be present at the time of diagnosis. Metastases to the pancreas can result in biliary or pancreatic duct obstruction, pain, or pancreatitis and may be resectable.

- CT and MRI findings may mimic primary adenocarcinoma of the pancreas but are more likely to show peripheral or homogenous contrast enhancement rather than the hypoenhancement of primary pancreatic adenocarcinoma.

- The roles of EUS and ERCP in metastatic disease of the pancreas are similar to those described for pancreatic adenocarcinoma. Diagnostic EUS findings in metastatic disease may be different than in pancreatic adenocarcinoma. DeWitt et al reviewed the EUS-FNA features in 24 patients with metastases to the pancreas and found that metastatic lesions were more likely to have well-defined margins than primary pancreatic adenocarcinoma.

- A recent report found that EUS-FNA confirmed the origin of metastasis in the majority of cases. Clinical history of a prior malignancy should prompt consideration of a potential metastatic lesion to the pancreas, therefore extra biopsies for immunostains or core biopsy should be considered.

- EUS-FNA by using a 22-gauge needle with immunostains has excellent diagnostic yield in patients with unusual, neuroendocrine, and metastatic lesions of the pancreas.

LYMPHOMA

- Primary lymphoma of the pancreas is extremely rare and can present as a focal or diffuse mass, frequently mimicking more common neoplasms such as adenocarcinoma or inflammatory processes such as pancreatitis.

- In 1 study, Khashab et al showed that EUS-FNA with flow cytometry was superior to EUS-FNA without flow cytometry in the evaluation of 16 patients suspected to have pancreatic primary pancreatic lymphoma.

- The endoscopic evaluation is identical to that of the more common pancreatic neoplasms. If lymphoma is suspected (eg, coexistent abdominal lymphadenopathy or other findings), a cytologic sample for flow cytometry or core biopsy should be obtained.

SCREENING FOR PANCREATIC CANCER

- In view of the dismal prognosis of pancreatic cancer at the time of diagnosis, screening programs have been proposed in the last decade in an attempt to detect pancreatic cancer at an early stage and potentially improve survival. Population-based endoscopic or image-based screening programs are not feasible or cost-effective, given the relatively low incidence of the disease.

- However, screening may be desirable in high-risk individuals. High-risk individuals include patients with hereditary pancreatitis, PeutzJeghers syndrome, Lynch syndrome, familial breastovarian cancer syndrome, familial atypical multiple mole melanoma, and familial pancreatic cancer syndrome.

- Accumulating data indicate that clinically available abdominal imaging tests such as EUS and MRI and/or MRCP can detect asymptomatic precursor lesions, such as intraductal papillary mucinous neoplasm, PanIN, and invasive malignant pancreatic neoplasms, such as ductal adenocarcinoma, in individuals with an inherited predisposition.

- Two large studies in screening in high-risk individuals reported their results. One study from the United States reported that screening of asymptomatic high-risk individuals frequently (42% of 216 patients) detects small pancreatic cysts, including curable, noninvasive, high-grade neoplasms. EUS and MRI detect pancreatic lesions better than CT.

- A Dutch study recently reported that EUS and/or MRI detected clinically relevant pancreatic lesions in 6% of high-risk individuals. Both imaging techniques were complementary. MRI was found to be very sensitive for the detection of cystic lesions of any size. MRI, however, might have some important limitations with regard to the timely detection of solid lesions.

RECOMMENDATIONS

- We recommend that imaging evaluation of patients with suspected solid pancreatic neoplasia include EUS and multidetector pancreas protocol CT scans .

- We recommend that EUS be performed for evaluation of pancreatic masses and suspected malignancy, particularly when CT detection or evaluation of resectability is equivocal.

- We recommend that biopsy of a suspected primary or metastatic pancreatic tumor should be individualized based on need for preoperative chemotherapy, resectability, and feasibility of surgery.

- We suggest that EUS-guided celiac plexus neurolysis be considered in patients with pancreatic cancer–related pain.

- We do not recommend preoperative ERCP in patients with obstructive jaundice because of resectable adenocarcinoma of the pancreas in the absence of cholangitis unless a substantial delay in operative resection of a symptomatic patient is anticipated.

- We recommend that patients with symptomatic, unresectable adenocarcinoma of the pancreas with biliary and/or gastroduodenal obstruction undergo attempted palliation with endoscopic stent placement as the preferred therapeutic modality.

- We recommend EUS FNA for localization and characterization of suspected pancreatic neuroendocrine tumors and metastatic solid pancreatic neoplasia . We suggest EUS-guided fiducial placement into a pancreatic malignancy if image-guided radiation therapy is considered.

- We suggest that screening with EUS and MRCP should be offered to high-risk individuals for pancreatic cancer.